GLASGOW
UNIVERSITY
LIBRARY

Professor McKendrick
with Author's Compliments

Sonderabdruck
aus der
Internationalen Monatsschrift
für
Anatomie und Physiologie.
Band XX.

Verlag von Georg Thieme in Leipzig.
1902.

Verlag von Georg Thieme in Leipzig.

Deutsche
medicinische Wochenschrift.

Begründet von

Dr. Paul Börner.

Redaction:

Geh. Med.-Rat Prof. Dr. **Eulenburg** — Prof. Dr. **Schwalbe.**

Vierteljährlich 6 Mark.

Probenummern stehen postfrei zur Verfügung.

Soeben erschien:

Lehrbuch
der
Anatomie des Menschen

von

Dr. **A. Rauber,**
o. ö. Professor an der Universität Dorpat.

Sechste Auflage.

ERSTER BAND:

Allgemeiner Teil, Lehre von den Knochen, Bändern, Muskeln und Eingeweiden.

Mit 1143 zum Teil farbigen Textabbildungen.

gr. 8°. 916 Seiten.

M. 17.—, geb. M. 19.—.

(Band II erscheint Anfang 1903.)

(Aus der Internationalen Monatsschrift f. Anatomie u. Physiologie. 1902. Bd. XX. Heft 1/2.)

(From the Physiological Laboratory, Cardiff, December 20th, 1901.)

The Structure and Functions of the hæmolymph Glands and Spleen.

By

Thomas Lewis, B. Sc.,
University of Wales.

University College London.

(With Plates I, II.)

Contents.

	page
I. Introductory	2
II. Historical	4
III. Anatomy and naked eye appearances in Vertebrata	8
A) Mammalia	8
1. Primates	8
2. Ungulata	10
3. Carnivora	12
4. Rodentia	13
5. Insectivora	15
B) Aves	16
C) Reptilia	16
D) Amphibia	16
E) Pisces	16
IV. Distribution in Vertebrata	17
V. Methods	18
VI. Minute structure	19
1. Microscopic Anatomy of a typical hæmal gland	19
2. Differences in the histological details between the glands of different animals	25
3. The "Head Kidney" of Pisces	28
VII. Vascular supply of the Hæmal glands of the rat	28
VIII. Nervous supply in the rat and dog	30
IX. Lymphatic supply	32
X. An account of Phagocytosis in the hæmolymph series of organs	32
1. The phenomena of Phagocytosis	32
2. Glands in which Phagocytosis occurs	37
3. Origin of Phagocytes	38
4. Nature of the pigment found in the glands	40
5. Relative degree of activity, as regards Phagocytosis, of the spleen and hæmal glands of the rat	42
XI. Function of the hæmolymph organs	43
XII. Development	45
XIII. On the structural inter-relationships of the various members of the hæmolymph series	46
XIV. Summary of chief Conclusions	50
XV. Bibliography	52
XVI. Explanation of plates	54

I. Introductory.

During the past twenty years nnmerous contributions have appeared at irregular intervals upon the subject of hæmolymph and lymphatic glands. The function, or functions of these organs seem however, until comparatively recently, to have been to a great extent misunderstood, and are even yet not duly appreciated.

The investigation recorded in the following pages, was commenced in the hope of giving a connected review of the numerous articles on this subject, and of clearing away some of the difficulties and discrepancies encountered by previous workers.

As the rat furnishes a ready and convenient source of fresh material, I have found it advantageous to make a careful examination of the glands in this animal the foundation of my work, extending it to similar and related organs in other animals. In this extension, which has necessarily been wide, the chief British mammals have been dissected; the general distribution of the structures has been recorded, and histological observations have in all cases been made. By the term "related organs" I signify such structures as the spleen, accessory spleens, ordinary lymphatic glands, and many intermediate forms. In regard to the nomenclature of these intermediate forms considerable confusion has arisen; in some cases they have been classed in the common category, "*hæmolymph glands*". In other cases this term has been restricted to such typical blood-red glands as are found in the horse, ox, or sheep. Yet again they have been designated "*hæmal glands*", or "*hæmal lymphatic glands*". So great has been this confusion that it is desirable to carefully define the different structures, and to make an attempt to fix a terminology which shall distinguish the various forms of glands.

As will be found from a perusal of the following pages, the glands may be divided into three classes, which are named, under the terminology proposed, according to the character of the fluid spaces found within them. In the first instance we may retain the term "*hæmolymph*", which was originally used by Lankester as a general term to include the red and white corpuscles of the blood; it seems

desirable to employ this term for blood-lymph structures generally, so that under the heading will fall all such organs as spleen, accessory spleens, hæmal glands, hæmal lymphatic glands, and lymphatic glands.

The statement has been made by Weidenreich [*19*a] that the spleen has no lymphatic supply; I am able to confirm him to this extent, that no purely lymphatic sinuses have been found in this organ. 1. To the spleen and to all other organs of the hæmolymph series *which are without these lymphatic sinuses*, the name *"hæmal gland"* will be applied, to signify that the fluid spaces found within them contain blood only. 2. Ordinary *"lymphatic glands"* are so called because their sinuses contain lymph only. 3. To intermediate structures, such as the "compound glands" found in the dog and cat, *which contain a mixture of blood and lymph in their sinuses*, the term *"hæmal lymphatic gland"* will be applied. These three varieties of glands will be referred to in the following article by the terms already mentioned[1]): but it may be well to point out at this stage that the nomenclature must not be too rigorously applied, as all intermediate forms are met with between the three types, in various animals: thus a gland may contain sinuses in which is seen abundance of blood, while the lymph is scanty; or there may be sinuses which contain a considerable amount of lymph, while the blood is inconspicuous. A complete series of organs thus exists, with the typical hæmal gland at one extremity, and the ordinary lymphatic gland at the other.

In using the words blood, or lymph sinuses, I wish to carefully avoid reference to the minute bloodvessels or lymphatic ducts, which may pervade the tissue of lymphatic or hæmal gland respectively. The terminology is entirely based upon the contents of the larger spaces which may be more properly designated *"sinuses"*.

The present investigation was suggested to me by Mr. Swale Vincent, Lecturer in Histology at University College, Cardiff, and I take this opportunity of thanking him for the generous advice he has given me on many points.

---

[1]) For the sake of convenience in the ensuing paragraphs I shall refer to typical blood red glands as hæmal glands, without including the spleen under this term.

II. Historical.

It is a curious fact that two series of observers, the one English and the other German, have been independently at work for many years upon subjects with a direct bearing on the present one, yet they seem to have been each unaware of the work of the other.[1]) As there is no mention in their accounts of the "*hæmolymph glands*" by name, or indeed any reference to the striking appearance, even to be naked eye. of the true "*hæmal glands*", it seems probable that the German writers have to a great extent worked at structures, which they would include under the general name "*lymphatic glands*".

The first English communication on the subject of bloodlymph glands was that of Heneage Gibbs [5a], as early as 1884. This was a short note on the histology of the structures found in the region of the renal artery and vein in man. Gibbs was of opinion that certain glands found in this situation, though closely resembling lymphatic glands, differ from the latter in that the lymph stream is replaced by blood.

In November 1890, Robertson [*12*] described the glands in more detail, dealing particularly with those found in the sheep, in which he estimated their number at from three to four hundred. Amongst the details of structure he observed elastic and involuntary muscle fibres in the adenoid tissue. The cells to which he attached most importance were nucleated cells, resembling red corpuscles, which underwent nuclear division, until they became giant cells containing as many as seven or eight nuclei. He asserted that these nuclei gradually lose their affinity for logwood and become stainable with eosin; and suggested that they might be freed as erythrocytes. In his conclusions, he stated that he considered the glands to have an important function in connection with the life history of the blood corpuscles. Gibbs' communication [5b] in 1893 was simply a note recognizing the work of the last author, and confirming his own previous observations.

[1]) A preliminary notice by Weidenreich [*19*b] has not long since come to hand, which appears to be the first German paper referring to the English literature.

Clarksons paper [*3*], which appeared in 1891, gave a further detailed description. The animals he examined were the sheep, horse, and pig, in which the glands were found, while in the camel, leopard, dog, cat, rabbit and rat he was unsuccessful in his search for them. He seems to have sought in the renal region only, though he suggested that possibly they might be discovered in other regions in the case of the sheep. It is indeed surprising he should have overlooked the very numerous and conspicuous glands already described by Robertson in this animal in the subvertebral region, and that those present in the dog, cat and rat should have escaped his notice. His examination of the camel and leopard probably gave negative results, because he restricted his search to a limited region. He laid stress on the presence of certain large cells, since called phagocytes, which he considered, from the examination of cover glass preparations, contained in many cases red blood corpuscles in the process of formation. His conclusion that hæmolymph glands have the important function of elaborating erythrocytes, was apparently based upon the appearance of a single phagocyte in a preparation of this character, which in his opinion was extruding a blood corpuscle; and also from the fact that globules, resembling erythrocytes of the sinus, were to be seen within the giant cells. He noted the presence of golden yellow pigment in his sections, but did not grasp its significance; his article concluded with a comparison of the general structure and arrangement of the lymphoid tissue of hæmal glands with that of the spleen.

The contribution of Vincent and Harrison [*16*] furnished a general and detailed account of hæmolymph glands in the ox, sheep, rat, dog and fowl, with a note on those in man. They were the first of the English writers to advance the view, that these glands are connected with blood destruction, considering the process to be similar to that described by Kölliker [*9*b] in the spleen. They described also the general appearance of the compound glands in the dog, now known as *"hæmal lymphatic"* glands; and Vincent [*17*b] subsequently noted similar glands in the cat. Vincent and Harrison were further of the opinion that these glands, namely *"hæmolymph glands"* are modified lymphatic glands and probably developed from them; also that they

form, with the spleen on the one hand and ordinary lymphatic glands on the other, almost a continuous series.

In January 1900, Drummond [*4*] contributed an article in which he confirmed the chief points of interest in the work of Vincent and Harrison, though he advanced but few new facts. He differed from the last observers in considering that the glands are not developed from ordinary lymphatic glands, and described somewhat more in detail the varieties of cells found in the *"hæmolymph glands"*. In addition he gave an account of the blood supply of the organs, throwing out a strong suggestion that the function of blood destruction may be cyclic.

The latest papers are three articles published by Warthin [*18*a, b, c], in American journals. He divides the glands into two varieties, which he terms *"splenolymph"* and *"marrowlymph"*, attributing the functions of blood destruction and blood formation respectively to these varieties. The marrowlymph glands are said to occur in the retro-peritoneal region only, and are possibly pathological. In his last publication [*18*c], he discusses the two varieties at more length. Warthin's work upon splenolymph glands is to a large extent confirmatory of previous observers, though with the important distinction that he has worked upon the human subject. In his latest contribution he also states, that he considers the reticulum of the sinuses is lined by flattened cells, forming two layers, between which larger cells (phagocytes) occur; so that the blood stream is not in actual contact with the reticulum fibres.

The German writers have apparently occupied themselves for the most part with the lymphatic glands of certain monkeys, although Leydig [*10*] seems to have the credit of being the first to describe bloodlymph glands, which he did as far back as 1857.

In 1889, Hoyer [*7*] described the process of phagocytosis in lymphatic glands.

Later Schumacher [*14*a, b] contributed an article, in which he described certain appearances in the "Lymphdrüsen" of *Macacus rhesus*. Amongst his other observations he noticed the lymphatic *"germ centres"*, and considered that some of these may be also situations in which

degeneration occurs, as he occasionally finds in them homogenous pigmented masses. The chief idea in his paper was based on the belief that the so called reticulum consists of branched cells, except inside the lymphoid nodules, and that these cells are capable of assuming phagocytic functions. In some places, near the capsule, Schumacher noticed these cells crowded together to form a dense mass, "*Zwischengewebe*", completely occluding the sinus at these points, and so crushed together as to have the appearance of solid rods of tissue. In these accumulations he frequently observed the process of karyokinetic division, the whole mass forming apparently the source of the phagocytes to the rest of the sinuses. Enclosed in the phagocytes he noticed not only erythrocytes, but occasionally, cells which he considered to be leucocytes, and in addition a certain number of rod shaped structures, staining red with eosin. He also gave an account of the cyclic function of the glands, which function he divides into three stages. In his second paper [*14*b] was given a more accurate account of blood destruction; he has observed amoeboid movements of phagocytes on the warm stage, but, no actual phagocytosis.

In 1898, Thomé [*15*] published a paper in which he advanced the view that phagocytes have their origin in the endothelium cells lining the capillaries of the "Lymphdrüsen" of certain monkeys, and stated that the smaller bloodvessels of the lymphatic tissue are lined by a tall, almost cylindrical endothelium. This statement I have been unable to confirm, but it is in accordance with the view of Böhm and Davidoff [*2*] in their account of the spleen.

Weidenreich's first paper [*19*a] was, as he stated, not based on personal observation as far as the bloodlymph glands were concerned, but in his second communication [*19*b] he makes some interesting statements of which the following are of the most important. He believes that the well known eosinophile leucocyte of the blood is possessed of its eosinophile granules, on account of its having taken up, while in a bloodlymph gland, particles of disintegrated erythrocytes; also that such leucocytes may be devoured by a giant cell. He thus supports a theory of direct and indirect phagocytosis. The remainder of his work is for the most part confirmatory of Schumacher.

more particulary in regard to the origin of phagocytes. He is persuaded that the endothelial lining of the sinuses exists only in places, and that the blood in consequence passes into spaces which are without a definite or continous cellular liuing. In his paper on the structure of the spleen, [*19*a] he denies the presence of lymphatic vessels either afferent or efferent, both in the spleen and in the so called "hæmo-lymph glands".

III. Anatomy and naked eye appearances in Vertebrata.

A. Mammalia.

1. Primates.

In *man*, hæmal glands have been described by several observers. Heneage Gibbs[1]) found them in the human subject in the neighbourhood of the renal artery and vein, and published a short account of their general appearance and histology. In 1890 they were further described by Robertson[2]), and later by Vincent [*16*] in a boy aged nine years as occurring in the mesentery in considerable numbers. A full description, both general and histological is to be found in the recent papers of Warthin already referred to. He finds them in the prevertebral retroperitoneal region and in the neighbourhood of the adrenal and renal vessels, also along the brim of the pelvis, in the root of the mesentery, rarely extending into the latter for any distance. Others are observed in the neck, and a few rarely met with in the omentum and appendices epiploicae. This description, as well as his account of the minute anatomy, corresponds very closely to that of other observers in lower mammals, with the exception of the mention of *"marrowlymph"* glands, the occurrence of which has as yet not been confirmed.[3]) He mentions four investigators, Rindfleisch, Weigert, Neumann and Orth, though without reference, as having noticed hyperaemic or hæmorrhagic lymphatic glands.

Saltykow [*13*] finds the glands present in 91% of cases, in an examination of 60 bodies.

---

[1]) Loc. cit. [2]) Loc. cit.

[3]) It is possible that these glands are forms of accessory spleens, for large multinuclear cells are frequently found in these organs.

In an examination of a *post mortem* subject, I have found the glands in large numbers. In the chest many glands were seen in the root of the lungs, in close proximity to the bronchi and bronchial vessels, for the most part posterior to them, and lined on the one side by pleura. A few were discovered in the prevertebral region, between the vertebrae and the aorta and oesophagus, losely embedded in fat or areolar tissue. In the abdomen the glands were even more numerous, occurring in the prevertebral retroperitoneal region behind the aorta and vena cava, forming a broken chain extending from the diaphragm, in front of the last dorsal the lumbar and upper two or three sacral vertebrae, into the pelvis. These chains of glands usually follow a large artery or its branches; thus the iliac arteries, both external and internal, are accompanied by such irregular chains of glands, which in the case of the internal extend well into the pelvis and are related to the side walls of the bladder and rectum. The Coeliac axis and all its branches likewise have glands in relation to them. A chain of glands was found along the lesser curvature of the stomach, accompanying the coronary artery and pyloric branch of the hepatic. A more incomplete chain, consisting in fact of but a few small inconspicuous glands of pinkish colour, existed along the greater curvature upon the course of the epiploic arteries. A few were seen in the neighbourhood of the duodenum, or more correctly in the root of the transverse mesocolon. In the mesentery of the jejunum and ileum a conspicuous chain was found at a distance of one inch from the gut. The superior mesenteric artery sends off its rami intestini tenuis, and these anastomose to form a series of arterial arcades, the branches from these anastomose and again form with each other a new series of arcades, and so on. The glands of the intestine were found between the branches from the last series of arches. In the mesocolon the arrangement was very similar, though the glands were even more numerous. Many of the structures were found behind the ascending and descending colon and caecum, which was in this case slung by a considerable mesentery. The glands in the transverse mesocolon were most conspicuous. A few small glands were also seen in the neighbourhood of the renal vessels, lying chiefly posterior to them.

In the *Monkey, (Macacus rhesus).* I have found numerous glands in the axilla and groin. Several large bodies also were seen in the neighbourhood of the termination of the common carotids. In the abdomen they occurred in the mesentery and transverse mesocolon, in bands $^1/_2$ inch from the gut, having a similar arrangement to those in man. A small gland was found under the left kidney. A few were scattered in the subvertebral region, embedded in fat, others in the pelvis in relation to the bladder.[1])

2. *Ungulata.*

In the *sheep, (Ovis aries).* The estimate of Robertson, that the number of glands, occurring in a single sheep, amounts to as much as three or four hundred, is probably not far wide of the mark. The glands, which are chiefly of the typical hæmal variety are spherical in shape, and not much larger than peas, though most of them are considerably smaller. They appear as small sacs of blood, which may have an arterial or venous colour, according to the time which they have been exposed: they are easily ruptured, the contents pouring out as a bloody fluid, which on examination shows the presence of the usual elements found in the sinus. These hæmal glands occur along the whole length of the subvertebral region, extending into the pelvis, and following as a general rule the course of the abdominal vessels and their branches. In the region directly over the bifurcation of the aorta, a remarkable group of these bodies[2]), sometimes as many as sixty to eighty in number, occurs; the glands are crowded together into a small area, and mixed with them are lymphatic glands and intermediate forms, with frequently brown coloured glands of various depths of tint. Occasionally a collapsed body, having otherwise the same general appearances, is met with. Other typical glands are found in different situations, particularly in the fat around the kidney and its vessels, also in the mesentery and

[1]) In *Cynocephalus Babouin*, a Baboon recently examined, numerous typical hæmal glands were found in the axilla and groin, and in the abdomen and thorax, following the course of the large bloodvessels, more particularly the aorta and common iliacs.

[2]) In a ram recently examined, this group was found to be absent.

in the mediastina. As a general rule they are found on the course of the bloodvessels, with which they are often closely associated, and from which they draw their blood supply.

In the *ox, (Bos taurus)*, the distribution of the glands, many of which are hæmal, is as follows. They are found in considerable numbers in the subvertebral fascia, along the course of the abdominal aorta and corresponding vein, lying in front, behind, and on both sides of it. Many of the organs are met with around the renal veins, deeply embedded in the perinephritic fat. In the pelvis they are also found, accompanying the branches of the iliac vessels, and a few have been observed of the hæmal lymphatic type in the groin and embedded in the muscles of the thigh. In the cow they occur at the base of the udder and after removal of that organ are exposed as a large mass consisting of numerous dark glands in close contact. In the steer this mass is replaced by two large glands of intermediate form. As to the general nature of the haemolymph glands in the ox, they are probably chiefly of the hæmal lymphatic type, though a number of the true hæmal glands are also found. Some of the former may be as much as 9 or 10 cms in length and 5 or 6 cms in breadth: many brown glands and intermediate forms occur. The last are chiefly found in the neck and in the mesentery, where they form a very constant belt, 9 or 10 cms wide, extending parallel to the gut, though at some little distance from it. In form the larger glands are never spherical, being occasionally oval, though usually very irregular. As a whole they are known to butchers as *"kernels"*, and their position is so very constant that in many cases they are valuable landmarks.

In the *horse, (Equus caballus)*, typical hæmal glands occur in considerable numbers around the renal vessels and in the neighbouring adipose tissue. They run to a length of from 2 to 3 cms and are the largest I have yet seen in any animal. They are chiefly irregular in shape, some are oval and a few spherical. In addition, there are a few scattered hæmal glands in the subvertebral retroperitoneal region, chiefly behind the aorta, and a few very typical glands on the wall of the bladder and pelvis. The total number of these bodies

is approximately fifty to sixty. Hæmal lymphatic glands or intermediate forms are exceedingly numerous, occurring in the axilla, groin, subvertebral region, roots of the lungs, and mesentery.

In the *pig* (*Sus domesticus*), hæmal glands are to be found in many cases in the subvertebral region, and in the fat around the stomach.

3. Carnivora.

In the *dog*, (*Canis familiaris*), the general distribution is very typical of that which obtains in several other animals to be presently described. The glands are of the hæmal lymphatic variety, nor have any hæmal glands yet been found in this mammal. On raising the kidney a large gland is often disclosed in close contact with the thoracic duct, embedded in perinephritic fat. It is usually the most typical found in the body. In addition there often exists a large "splenic group" of glands, situated on the splenic vessels, and easily exposed by drawing the stomach over to the right side. Other glands frequently occur in the subvertebral region, extending into the pelvis, lying also beneath the aorta and iliac vessels. A few more, closely resembling ordinary lymphatic glands, are seen in the neck. These bodies are all of a yellowish colour, irregularly blotched in places with red. They are very irregular in shape, and are often closely adherent to surrounding fat: they vary in length from $^1/_2$—2 cms. Dissections have been made of the vascular and nervous supply, which closely resemble the same systems in the rat, under the heading of which it is intended to describe them. The lymphatic supply of these hæmal lymphatic glands is very striking; the vessels appear as transparent thin walled tubes often measuring as much as $^3/_4$—1 mm in diameter, and consequently may be found without difficulty. As their arrangement has been more thoroughly worked out in the cat, in which they are practically identical with those under consideration, they will be described in that connection. I wish to lay stress upon the general arrangement in the dog, as it is not only typical of the carnivora, but also of many rodents.

In the *cat*, (*Felis domestica*), the arrangement is almost identical with that already detailed in the dog. The glands, which are all

of the hæmal lymphatic variety, occur constantly in the renal region, one on either side of the body, and often in contact with the thoracic duct. The splenic group is not so constant as in the dog, but a good many glands are as a rule to be found in the subvertebral region and in the mesentery.

After feeding a cat for some time upon milk, the animal was killed and quickly opened. The lymphatic ducts were filled with chyle, and were easily traceable, on account of the natural white injection contained in them. The hæmal lymphatic glands of the mesentery were found to have a large supply of afferent lymphatic vessels, piercing the capsule at irregular intervals. As a rule, one large efferent vessel proceeds from the gland in the direction of the thoracic duct.

In the *ferret.* (*Putorius furo.*) It is only necessary to state that the glands occurring in the ferret are all hæmal lymphatic glands, that they are abundant, and have much the same arrangement as in the dog and cat. The lymphatic supply is also very conspicuous.

In the *stoat* (*Putorius erminea*) and the *weasel* (*Putorius vulgaris*). The hæmal lymphatic glands of these animals show a similar distribution to those of the ferret, but are as a rule, not so numerous.

4. Rodentia.

In the *rat.* In addition to the common *brown rat* (*Mus decumanus*) other species have been dissected, including the *black rat* (*Mus rattus*), several varieties of tame rats (*Mus alexandria*) and albinos. As I have made a particular study of the position of the glands in these animals, a rather extended account of their general distribution is necessary. It cannot fail to strike the observer, after the examination of a number of these rodents, that the hæmolymph glands found in them, show a remarkable constancy in position and in number. The arrangement in over forty rats examined has been observed as practically identical in all. On raising the kidney and carefully tearing away the loose fatty tissue posterior to it, one of the glands is seen lying in the deeply pigmented fat directly anterior to the renal vessels; occasionally two of the organs in close proximity occur in the place of a single larger one; and in many cases one or more similar bodies

are observed further towards the anterior end of the kidney than the last.

These glands may be considered of the hæmal type, though a complete peripheral sinus is rarely present; they are as a general rule flattened oval bodies, varying from $^1/_2$—4 mm in length, and about half that breadth. Their colour varies very considerably, but in the renal region they usually contain more blood or pigment than in other situations. Sometimes they have assumed a bright red colouration, in other cases they are brown, occasionally they may be pink or light brown, and still more seldom mottled red and brown. The colour is usually confined to one surface of the organ.

In further references to this group I shall use the term *"renal group"* (pl. I. fig. 7 *r.g*).

Another large and exceedingly constant group of glands is found in the fold of peritoneum slinging the spleen and stomach. These (pl. I. fig. 7 *s.g*) occur on the course of the splenic vessels. They vary in number from 3 to 10, and are most numerous in the common brown rat. It is often quite impossible to distinguish these glands, which I shall in future refer to as the *"splenic group"*, from ordinary lymphatic glands by naked eye observation (so much do they resemble them); for they are occasionally quite white or yellowish, though usually blotched with red (fig. 7 *s.g*), the blotches indicating the position of the *"peripheral sinuses"*, occurring within them. In many cases a red zone is seen encircling the gland peripherally; in rare cases they are a full blood red; yet others are tinged brown of various depths. Though usually spherical, one or more may be lenticular; their diameter varies from $^1/_8$—3 mm.

This description applies more particularly to albino rats, and tame rats generally; in the wild rat they are always more numerous, and contain more blood or pigment. In the wild rat, too, a few black glands, which are lobulated, occur dorsal to the stomach, and otherwise have the general appearances of ordinary lymphatic glands.

The opinion has been already expressed that the glands, of the animal under consideration, are of the hæmal variety, as I have been unable to trace any lymphatic vessels to them, nor are lymph corpuscles

present in any numbers in the sinuses. There is nevertheless something in the general arrangement of lymphoid tissue and sinus in these organs, which is not found in the typical glands of the ox and sheep. Vincent and Harrison classed them with the compound glands in the dog. The general arrangement of the tissues is certainly similar, but they are by no means of the same variety.

In the *mouse*. Several individuals of the species of common *house mouse* (*Mus domesticus*) have been dissected. In these the arrangement is so similar to that, which obtains in the rat, as to need no special description. The glands are less numerous and are less vascular than in the latter.

In the *rabbit*. (*Lepus cuniculus.*) Hæmolymph glands are only occasionally met with in this animal. When they do occur they are pinkish or brown in colour, and are small and inconspicuous, resembling both in colour and size those of the "splenic group" in the rat. They occur most frequently in the subvertebral region, and in those situations where lymphatic glands are usually found.

In the *guinea pig, (Cavia cobaya)*, splenic and renal groups are found fairly constantly. The glands forming these groups are of irregular form, and to naked eye inspection resemble those of the dog. I have however been unable to trace lymphatic vessels to them and am doubtful as to whether they may be classed with the splenic group of glands in the rat, or the hæmal lymphatic glands of the dog, though I am more inclined to consider them of the same variety as the former.

In the *squirrel* (*Sciurius vulgaris*), the arrangement is very similar to that in the rat. The same may be said of the *water vole (Arvicola amphibius)* and *short tailed field mouse (Arvicola agrestis)*.

5. *Insectivora.*

At present the only individual examined has been the *mole* (*Talpa europæa*).[1]) The glands were found in the renal and splenic regions, and from naked eye appearances seemed to be of the hæmal type.

---

[1]) The glands have since been found in the Hedgehog (Erinaceus Europæus). They were seen in the renal and splenic positions. In neither have they been microscopically examined.

B. Aves.

Our present knowledge of the distribution of hæmolymph glands in birds is not abundant. Vincent and Harrison[1]) have seen them in the *fowl* and *turkey* (*Gallus bankiva* and *Meleagris gallopavo*), one occurring in the former below the sternum, others in the fat surrounding the stomach and rectum. I have searched in a number of birds, including the *pigeon*, *rook* and *jackdaw*, but have only seen them in the fowl, and one small solitary gland, typically hæmal, in the omentum of a *pheasant* (*Phasianida colchicus*). Those found in the fowl occurred in the neighbourhood of the stomach, and in the neck, and were small spherical bags of a blood-red colour, about 1 mm to 1 cm in diameter.

C. Reptilia.

No hæmolymph glands have as yet been discovered in this group of the Vertebrata.

D. Amphibia.

Two small bodies, closely resembling typical hæmal glands in appearance have been found in the *toad* (*Bufo vulgaris*), and were situated on the surface of the gall bladder. These were probably accessory spleens.

E. Pisces.

Balfour [*1*] described the "*head kidneys*" in ganoids and teleosts as consisting of adenoid tissue, and in many cases noticed the presence of blood sinuses. In 1897 they were further described by Vincent [*17* a]. In the contribution of Vincent and Harrison[2]), a short paragraph is devoted to these organs, in which their similarity to hæmolymph glands is noted in the case of Cyclopterus lumpus. The pronephros or "head kidney" of fishes forms in adult teleosts and ganoids, as is well known, the degenerated adenoid anterior end of the kidney. It is composed, as will be further described, of adenoid tissue and blood sinus.

---

[1]) Loc. cit. [2]) Loc. cit.

In *Anguilla anguilla*, Vincent[1]) states that he has found one or two typical hæmolymph glands, embedded in the abdominal fat, though he has not given details of the minute structure.

IV. Distribution in Vertebrata.

The account, which has just been given of the general anatomy of hæmolymph glands, deals only with the distribution of the glands in each of the individuals examined. When a comparison is made of the different examples of the several groups certain interesting points may be observed.

The *mammals* examined have been nembers of five orders, *Primates, Ungulata, Carnivora, Rodentia, Insectivora.* In the first two of these, *typical hæmal* glands have always been found; and they appear to be restricted to these two orders. Thus they have so far been noticed in man, monkey, sheep, ox, horse, goat and pig, and in no other animals. We may therefore say, that as far as is known, *typical hæmal glands are characteristic of the Primates and Ungulates.* On the other hand in the group *Carnivora no hæmal glands, but only hæmal lymphatic glands are found,* and these seem to be constantly present in *"renal"* and *"splenic"* groups. Of the Carnivora the following species have been examined, and in all, the distribution was found to be similar: — dog, cat, ferret, stoat and weasel. In the group *Rodentia*, there exists a type of gland which may be called "hæmal" but which differs in several respects from the hæmal glands of Ungulata. The species examined include the rabbit, several varieties of rats and mice, and the guinea pig, squirrel, water vole, and shrew. In the Guinea Pig the glands appear to be intermediate forms, which can hardly be definitely called either "hæmal" or "hæmal lymphatic".

Several observers have failed to find the glands in certain mammals; Clarkson[2]) could discover none in the camel and leopard, while Vincent and Harrison[3]) failed to find them in the hedgehog.[4]) But the same observers failed to find the glands present in a number of animals examined, in which they undoubtedly exist. I believe, that

[1]) Loc. cit. [2]) Loc. cit. [3]) Loc. cit.

[4]) As already observed, they have since been seen in the hedgehog.

either *hæmal or hæmal lymphatic glands will be found in all the mammalia:* I have at any rate found them in all mammals dissected.

In *Birds* the distribution seems to be very much less constant. Typical hæmal glands have been found in the fowl, turkey and pheasant, but in many others, they have been searched for in vain.

In *Reptiles* and *Amphibians* it is doubtful whether hæmal or hæmal lymphatic glands exist at all, except in the case of one organ, the spleen.

In *Fishes*, a few bodies having the same naked eye appearances as typical hæmal glands were described in the silver eel: further in almost all Teleostean fishes the anterior end of the kidney has a similar structure to hæmal glands.

Thus it would appear that hæmolymph glands are most characteristically developed in the higher forms of vertebrate life, or those in which the red blood corpuscles are non-nucleated.

V. Methods.

In the preparation of material for microscopic examination, numerous methods have been employed. I have examined fresh preparations, including cover glass specimens, sections with the freezing microtome, and teased preparations of the various parts of the glands, after treatment with various stains. The bulk of the tissues however have been fixed and hardened in one or other of the following fluids: — *"corrosive sublimate solution"*, *"alcohol"* of various strengths, *"Müller's fluid"*, *"Zenker's mixture"*, *"acetic bichromate solution"*, or *"Flemming's fluid"*. After hardening, the tissues were washed, dehydrated, soaked in *xylol* or *cedar wood oil* and subsequently embedded in *soft* or *hard paraffin*. I have obtained very good results with *"corrosive sublimate"* or *"acetic bichromate"* solutions, but for details of cell structure *"Flemming's solution"* has been employed to most advantage.

In the majority of cases the sections were cut with the rocking microtome and mounted on albuminized slides, after carefully floating out on water. In staining I have used *hæmalum, carmalum, eosin, picric acid, borax carmine, methyl blue, methylene blue, toluidene blue, acid fuchsine, methyl orange, saffranin, magdala red*, and other dyes.

Silver nitrate impregnation has been used in particular cases, and *Heidenhain's iron alum* method in addition to *saffranin*, in combination with *light green* or *gentian violet*, to demonstrate nuclear figures and other cell details. *Hæmalum and eosin* have been employed in the case of almost all glands for purposes of comparison, because they give so good a contrast between adenoid tissue and blood sinus. This combination is further particularly well adapted to cases where phagocytosis is to be studied. Saffranin in conjunction with a suitable plasma stain, gives very beautiful results after hardening the material stained in *Flemming's solution*. The aniline Blues have been useful in preparations of reticulum.

VI. Minute structure.

1. Microscopic Anatomy of a typical hæmal gland.

It will be advisable to give in the first instance, a description of the minute structure of a typical blood-red hæmal gland, such as one meets with in the ox or sheep, and to subsequently note the points of difference between the histology of this type, and that of other varieties. The general arrangement of the tissues has already been described by previous observers; a short account will consequently here suffice.

This account may be conveniently given under the three headings, 1. *Capsule and Trabeculae*, 2. *Sinuses*, 3. *Adenoid tissue*.

The *adenoid tissue* lies for the most part towards the centre of the gland, and is of irregular form, for it is cut up by the "*central sinuses*", which communicate with the "*peripheral sinuses*" lying immediately beneath the capsule. The central sinuses are chiefly in the form of offshoots from the peripheral sinus, and they frequently communicate to form an irregular network in the centre of the lymphoid mass. The greater area of sinus, as seen in sections, belongs to the peripheral portion: this again is limited externally by a strong "*capsule*" from which numerous fibrous processes or "*trabeculae*" project inwards, running into the adenoid tissue and further subdividing it. As a general rule these trabeculae, when present, are accompanied by surrounding sinuses, and eventually end by breaking up into finer and

finer strands, which terminate as the reticulum of the adenoid tissue and sinuses. The character of the "*endothelium*" which lines the capsule, the trabeculae, and lymphoid tissue, will be further discussed. Having given the general relations of the three chief elements of the gland, I proceed to a more detailed account of these constituent parts.

The capsule and trabeculae. A capsule is always present, in certain cases consisting of both fibrous and serous layers, as in the case of the spleen and many lymphatic glands. It varies in thickness with the size of the organ, and the animal examined. Its histological composition, as might have been expected, is similar to that of the capsule of other related organs, consisting chiefly of white fibrous tissue, with some yellow elastic fibres and involuntary muscle. Strips of the capsule impregnated with silver nitrate show the arrangement of the white fibres very beautifully (pl. II. fig. 14) the fibres remaining unstained, while the ground substance is darkened.

From the inner side of the capsule spring trabeculae composed of the same elements as the capsule itself. These subdivide the gland as above described, and vary considerably in strength and arrangement in different animals. The capsule is pierced at one or more points by various nerves and bloodvessels; the latter are conducted along the trabeculae in the large glands; in other cases they run in strands of adenoid tissue (pl. II. fig. 13).

The *lymphoid tissue* is composed of a dense reticulum, in the meshes of which leucocytes are enclosed; in many cases it is nodulated, and rounded projections jut into the sinus. In these rounded masses, which are found by an examination of serial sections to be connected to the main mass of adenoid tissue, there often occur spherical patches which stain less deeply than the surrounding tissue; these constitute the "*Germ centres*" or "*Keimcentra*" of the German writers (pl. I. fig. 1). The cells contained in them, seem slightly swollen and shew active signs of mitosis. Around the margin of the germ centre the cells assume a darker stain gradually shading off into the general adenoid tissue (pl. I. fig. 6).

The presence of these centres in hæmal glands was originally observed by Robertson and has since received attention from several

observers. Involuntary muscle fibres (pl. I. fig. 9 *i.m.f*) and elastic fibres occur in the lymphoid tissue, but by no means in large quantity. Care must be taken not to confuse the elongated cells of the endothelium lining the capillaries, which everywhere pervade the lymphoid tissue, with involuntary muscle fibres.

Warthin[1]) states that he has found free red cells in the adenoid tissue, but the presence of these cells is extremely doubtful. They are certainly seen in the lymphoid tissue, but careful observation reveals the fact that they are in capillaries, the walls of which are often indistinct. Free red corpuscles in the adenoid tissue exist only in places where the delicate endothelium is absent; whether this is due to the breaking away of these endothelium cells to form phagocytes, or whether they do not exist in these situations, it is difficult to say.

Masses of dark yellow or brown pigment are seen frequently in the adenoid tissues in the neighbourhood of the sinuses, though such masses are not so often seen in the case of the sheep as in the rat. They are darker than the corresponding granules found within the phagocytes of the sinus, probably on account of the greater accumulation at these points, and of the fact that much of the pigment constituting them is in a free state (pl. I. fig. 8).

The various forms of cells found in the lymphoid tissue have been fully described by more than one observer: for the sake of completeness I append the following description given by Vincent and Harrison[2]), which agrees more closely with my own observations than does any other.

"The following cells were found: —

1. The most numerous, small cells, 4—5 μ in diameter, almost entirely composed of nucleus, but with a thin ring of protoplasm (pl. I. fig. 9 *leu*).
2. Cells with similar characters, but more abundant protoplasm.
3. Cells larger than the preceeding, with large pale nuclei oval or crescentic in form.
4. Large multinuclear cells, containing as many as 7 or 8 nuclei.

---

[1]) Loc. cit. [2]) Loc. cit.

5. Large faintly granular cells stained with eosin, diameter 20 μ.
6. Cells smaller than the preceeding with large pale nuclei oval or crescentic in form."

Variety 5. I have not observed, and the multinuclear cells have been but very rarely seen in any of the glands, though frequently met with them in sections of spleen.

The *sinuses.*[1]) In addition to the sinuses both peripheral and central above described, other minor sinuses occur in the capsule itself. These are small and narrow, and are most abundant in certain glands with thick capsules. The sinuses contain the usual constituents of the blood stream, and in addition phagocytes in all stages of activity.

The eosinophile blood corpuscle has attracted as already stated the special attention of Weidenreich[2]) who believes that ordinary leucocytes take up erythrocytes and partially disintegrate them, with the formation of eosinophile granules. The leucocytes are then supposed to join the general bloodstream, in which they form the well known eosinophile cell. This striking and ingenious theory has several serious objections. In the first place it would be expected, by analogy, that the action of leucocytes upon ingested blood cells would be similar to that of phagocytes, and would not cease at the mere setting free of hæmoglobin. Secondly, according to *Kanthack* and *Hardy* [8], the application of suitable stimuli to such cells in the blood stream, causes them to actively increase. How would this increase of eosinophile corpuscles proceed, without the ingestion of further red blood corpuscles, to compensate the loss of eosinophile particles in the individual cells?

The question as to the nature of reticulum and endothelium has received considerable attention in lymphatic glands and spleen, but has not yet been thoroughly worked out in hæmal glands. In examining these elements, I have employed the methods now usually in

---

[1]) Drummond loc. cit. p. 203 makes the statement that in the larger hæmolymph glands there are no blood corpuscles either in the central or peripheral sinuses. If this be the case, by what right are they called "hæmolymph" glands at all?

[2]) Loc. cit.

vogue for studying the framework of glandular organs. In some cases the fresh tissues have been cut with the freezing microtome, and subsequently treated with a 5% solution of caustic potash; in other cases they have been submitted to tryptic digestion, or the blood has been removed from the sinuses by washing with distilled water. Yet again, the entire gland was first hardened in alcohol, treated with a 1% solution of caustic potash, and afterwards transferred once more to alcohol. The further treatment was as follows: — the gland was either stained in bulk, or mounted unstained in paraffin, and sections were then cut and mounted.

In the study of a number of preparations by these different methods, I have observed little or no difference between the structure of reticulum in these and related glands. My observations on the general arrangement of the tissue agrees with the description given by Professor Schäfer[1]) in ordinary lymphatic glands. Fibrous connective tissue forms the foundation of the whole organ, and it is most compact in the capsule and trabeculae, consisting essentially of bundles of white fibres; fine strands pass from these in every direction, forming a dense meshwork which supports the other tissue elements of the gland. The reticulum is very dense in the adenoid tissue, but more sparse in the sinuses: between sinus and lymphoid tissue, or, more correctly, in the outermost part of the lymphoid tissue, the reticulum becomes denser (c. f. spleen, pl. II. fig. 16). A question of considerable difficulty arises with regard to that portion of the reticulum which bridges across the sinuses. It has been regarded by Schumacher and others as consisting of numerous branched cells, the processes of which interlace, giving rise to the characteristic appearance of a network: and it is noticeable that many of our standard text books illustrate it as having this structure, in the case of lymphatic glands. Recent observers, in particular Höhl [*6*], consider that the reticulum consists of a fibrous network with flattened cells, which he calls "*reticulum cells*", attached to it. In the case of the hæmal glands this is certainly the arrangement, although the nature of the reticulum cells themselves appears at present not to be clearly understood.

[1]) Quains Anatomy. Vol. III. Part IV. p. 296.

Here arises a question of much importance. *Are the cells lining the reticulum fibres continous with the endothelium cells bounding the sinuses?* If so, the two varieties of cell are probably of much the same nature; or in other words, the reticulum cells are nothing more than modified endothelium cells. Careful search has convinced me that such a continuity exists. Cells of the endothelium proper show the appearance of being directly continuous with cells lining the reticulum. Moreover, comparison of the shape and size of the two varieties of cell, lends support to the view that there is one more or less continuous lining for reticulum, capsule and adenoid tissue. The endothelium lining the sinus, and separating it from the adenoid tissue, is nothing more than a layer of endothelium cells, attached to the somewhat denser reticulum fibres found in the outermost part of the adenoid tissue. It appears more striking in this situation, not only because the cells are more numerous, but because of their more regular arrangement, and the fact that there are no cells found lining the neighbouring reticulum fibres in the lymphoid tissue. The endothelium lining the reticulum will probably not form an absolutely continuous lining over it, so that in some places it will be washed by the blood stream. A loss of endothelium cells may occur, either mechanically in the section cutting, or during the living state to form phagocytes. In the reticulum a few scattered involuntary muscle or yellow elastic fibres are met with occasionally, and these have already been observed in the lymphoid tissue.

If this view of the continuity of the endothelium lining be correct, the blood sinuses may be regarded as nothing more than a coarse capillary meshwork, or they may be looked upon as a system of veins, similar to that described by Böhm und Davidoff [1]) in the spleen; for the sinus is broken up by strands of reticulum, lined on all sides by endothelium, into a network of short communicating channels, which may be regarded as short irregular capillaries. I prefer to regard these vessels as capillaries and not venules, as the endothelial lining, bounding them is directly continuous, through that lining the outer wall of the so

[1]) Loc. cit.

called sinus, with the endothelium lining certain arteries and veins entering the hilus of the gland (pl. I. fig. 5). Furthermore the endothelial walls of the capillaries, leading from the sinus into the adenoid tissue, is also directly continuous with the lining of the sinus itself (pl. I. fig. 5 *e. c c*).

The advantages derived from the breaking up of the sinuses by the reticulum are many. In addition to forming a support for the lymphoid tissue, the reticulum retards the velocity of the blood stream by increasing the resistance; also the phagocytes are enabled to retain their position, and are not swept into a heap in one portion of the sinus. Furthermore, if the phagocytes derive their origin from endothelium cells, as I believe to be largely the case, the opportunity of multiplication is increased proportionally with the increased area of endothelium. These conditions all facilitate the process of Phagocytosis.

The endothelium seems, from an examination of silver nitrate preparations of capsule (pl II. fig. 14), to have much the same appearance in this situation as that covering the inner wall of blood vessels generally. The particular cells lining the reticulum seem to be more branching however, and are probably more irregular, an adaptation to the irregular fibres which they encase.

2. *Differences in the histological details between the glands of different animals.*

Primates. The microscopical characteristics of hæmolymph glands in *man* and *monkey* have been examined. In both these species "hæmal" glands occur. The peripheral sinus is small or disconnected, the trabeculae weak; but the central sinuses are numerous and break up the lymphoid tissue considerably. Germ centres are scarce, though phagocytosis is frequently observed.

Ungulates. The trabeculae in the hæmal glands of the *ox* are strong and numerous; the peripheral sinus is often small, but the central blood spaces are abundant. Germ centres are scarce and phagocytosis is rarely noticed. In the *sheep*, the sinuses are much larger, particularly the peripheral; the trabeculae vary in strength with the size of the gland; the reticulum is fairly dense, as is always

the case when the sinuses are wide. Germ centres are plentiful and a good many phagocytes are scattered throughout the sections. In the *horse*, the sinuses are often broken up by strands of lymphoid tissue; the germ centres are very frequently seen in the cortical portion of the lymphoid tissue. Signs of phagocytosis are occasionally observed. In the *pig*, the chief feature is the strength of the trabeculae, which to a large extent subdivide the organ. In these glands I have not observed phagocytosis proceeding, but occasionally small masses of pigment occur in the sections: destruction of erythrocytes probably occurs to a slight extent.

Carnivora. The glands all have a very characteristic appearance (pl. I. fig. 3). There is never a complete peripheral sinus present; blood spaces are only found in certain restricted areas beneath the capsule. There is usually a large sinus in the centre of the gland, which communicates with the peripheral sinuses by numerous small interlacing minor sinuses; these last mentioned are smaller than any met with in glands of the Ungulata or Primates and seem to be characteristic of *hæmal lymphatic* glands. *They contain both blood and lymph in abundance, and probably have direct communication with both blood and lymph streams.* It is of course quite possible that both blood and lymph sinuses are separately present, with but a thin partition between them, and it is within the bounds of possibility that erroneous conclusions may be sometimes drawn from injection experiments, through the breaking down of such a partition. I am more inclined to the view that *one system of sinuses exists which contains blood and lymph,* since I can observe no histological differences between the details of different sinuses; also injection of the sinuses by the blood or lymphatic vessels shows that they are both connected with one and the same system of sinuses.

There exists in these glands therefore admixture of blood and lymph streams. Large efferent vessels may be traced from these glands to the thoracic duct, and it might be expected that blood would be found in these.[1])

[1]) In the case of a dog examined, an efferent lymph vessel, passing to the thoracic duct, was observed to contain a considerable amount of blood, this has

In hæmal lymphatic glands, reticulum is abundant in the sinuses and signs of active phagocytosis are always present; germ centres are plentiful, situated usually near the outer border of the adenoid tissue. In the cat they are found more frequently than in the dog, though in this animal the sinuses are less irregular and numerous.

In *Rodentia* the glands have a structure differing slightly from typical hæmal glands. In *rats* a complete peripheral sinus is never present; the lymphoid tissue in the case of the glands of the *renal group* is collected to one side of the organ, while the other half is occupied by a large sinus. From the adenoid tissue finger shaped masses project and run through the sinus towards the capsule of the opposite side: in these processes blood vessels pass to the lymphoid tissue (pl. I. fig. 5; pl. II. fig. 13). Germ centres have been found in one gland only, in which they were numerous. Trabeculae are usually absent, and this may account for the unusual collection of the adenoid tissue to one side of the gland, in contact with the capsule.

In the *splenic* glands, the sinuses are distributed throughout the lymphoid tissue, which is consequently broken up; they come to the surface in certain places only, giving the blotchy appearance which is so characteristic of the glands in this region. Signs of active phagocytosis are always present, though the sinuses do not contain many leucocytes. In the *rabbit* the arrangement is somewhat similar, but the blood sinuses are broken up by very numerous fine strands of adenoid tissue and small trabeculae. Compared with the renal hæmal glands of the rat the sinuses are small though very distinct, and completely filled with phagocytes. This abundant blood destruction appears to be characteristic of the glands of Rodentia, and is by no means limited to the rabbit.

In the *guinea pig*, large masses of lymphoid tissue and many germ centres occur, while the sinuses are small and broken up. Though closely resembling hæmal lymphatic glands when observed *in situ*, microscopic examination shows them to be similar to the splenic glands of the rat.

---

frequently been observed by those experimenting upon the result of obstruction of the inferior vena cava on the flow of lymph.

Aves. In the *fowl* the sinuses and lymphoid tissue are considerably mixed, and are not so easily distinguished from one another. The former are filled with nucleated blood corpuscles, and here and there phagocytes, crowded with pigment or containing several red cells, are met with. Quantities of pigment in a free state are also seen in the adenoid tissue, particularly towards the margins of the sections.

3. Head kidney of Fishes.

I have examined many species of teleostean fishes including *Hypoglossoides limandoides*, *Trigla lyra*, *Salmo salar*, *Rhombus laevis*, *Pleuroneetes flesus*, *Cyclopterus lumpus*, *Esox lueius*, *Molva vulgaris* and *Cottus gobio.* In some of these the structure of the head kidney (pl. II. fig. 10), consists of adenoid tissue pervaded in many places by a definite blood sinus, containing closely packed nucleated blood cells. The adenoid tissue consists of numerous leucocytes contained in a dense reticular meshwork, and is frequently marked off from the sinuses by an irregular endothelium. In a few, little adenoid tissue is present in the head kidney, the organ having the appearance of a large blood sinus with a dense reticulum. This is well seen in *Rhombus laevis* and *Pleuroneetes flesus.* In others lymphoid tissue forms the bulk of the gland, and only a few very distinct sinuses are present, e. g. *Hypoglossoides limandoides.*

Acipenser sturio is the only ganoid which has been examined. The head kidney consists chiefly of adenoid tissue with here and there small indefinite blood sinuses containing nucleated corpuscles (which were also found in the lymphoid tissue).

No phagocytosis has as yet been observed in these head kidneys.

VII. Vascular supply of the hæmal glands of the rat.

Little attention has been paid to this important part of the anatomy of the hæmolymph glands. Drummond devoted a paragraph to the circulation, but he states that no good specimens were obtained in the dogs which he injected, as he could not distinguish hæmal lymphatic, from lymphatic glands, after the injection. His description was based upon an examination of serial stained sections. This

method of tracing blood vessels seems one which is scarcely likely to give satisfactory results. At any rate I am unable to confirm the account given by Drummond of the vascular supply. The difficulty, of being unable to identify the glands after injection, is easily remedied by noting the position of the glands before commencing the operation.

The arteries and veins have been separately injected in the rat directly after death with a warm carmine gelatine mass. The animals were placed on one side until the injection hardened, when the glands were excised and embedded in paraffin. Serial sections of a thickness of from 10—20 μ were then cut.

I find that one or more arteries enter the hilum of a gland; these spring in the case of the *splenic group* from the *splenic* artery, and in the case of the *renal group* from the *renal* arteries (pl. I. fig. 7). On reaching the capsule they break up into several branches, of which one or more opens *directly into the sinus*. The wall of such an artery is continuous with the capsule of the gland. Other arteries proceed across the sinus, being conducted in the gland of a rat, in which trabeculae are rarely found, by cords of adenoid tissue, to the general mass of lymphoid tissue[1]) (pl. I. fig. 5; pl. II. fig. 12 and 13). Here they branch into smaller and smaller vessels and eventually form a capillary network.

In preparations in which the *arteries* were injected the sinus was engorged with the red mass (pl. II. fig. 12), so that this portion of the gland appeared on section of a uniform red colour, except for the regular interruption of reticulum fibres and phagocytes, which give such sections of the sinus a characteristic network appearance. From the border of the sinus adjoining the lymphoid tissue small vessels or capillaries run into this lymphoid tissue (pl. II. fig. 12 and pl. I. fig. 5 *c.a*).

After injection of the *veins*, sections of the glands showed very different appearances; in some cases no injection had found its way into the sinuses, though minute capillary networks were picked out

[1]) I have not found blood vessels or capillaries lying free in the sinus; they invariably have this sheath of adenoid tissue.

in the adenoid tissue (pl. II. fig. 13). In other cases a certain amount of the coloured gelatin was seen here and there in the sinuses (pl. II. fig. 13 *s*), in no case were the sinuses filled with injection, as they are after injecting the arteries. I believe that the small capillaries, alluded to above and seen in pl. I. fig. 5 *c.a* open from the sinuses and join minute veins; these are joined by other minute veins from the adenoid tissue, which return the blood from the small arteries and capillaries of the same, to form larger veins; these course towards the hilum, always increasing in size as tributaries join them, until, leaving the general lymphoid mass, they are conducted along the finger shaped processes of the adenoid tissue, which they ultimately leave by piercing the capsule. In addition to these veins, others (pl. I. fig. 5 *v*) spring directly from the sinuses, having a connection with the sinus similar to the entering arteries. These are protected by valves, which prevent the direct injection of the sinuses by the veins, giving in injected specimens the appearance seen in pl. II. fig. 13.

The veins from the splenic hæmal glands join the splenic vein and ultimately the portal; those draining the blood from the renal group may be traced to the renal veins (pl. I. fig. 7).

The general structure of the capillaries and small blood, vessels as seen in sections exhibits no extraordinary features. Thomé, who worked with certain "Lymphdrüsen" of the monkey, has stated that the endothelium cells lining them are in many cases almost cylindrical, but I have been unable to find this appearance in any gland examined. The cells are flattened or spindle-shaped as in the case of other capillaries, and are continuous with those lining the sinuses. Thomé also believed that phagocytes take origin from these cells. I have not noticed any appearances which could justify me in confirming him, though it is probable that phagocytes arise from cells directly continuous with these.

VIII. Nervous supply in the rat and dog.

The nervous supply to the hæmal glands has hitherto received no attention. I have studied it in the rat and dog, particularly in the former, and find the main features identical in both.

The method originally intended was that used by Chevrel [1]) for the display of the sympathetic nerve fibres in fishes. Osmic acid is painted on the dissection, with the result, in fishes, that the nerves stain black while surrounding tissues remain white. In attempting this method upon mammalian material the result has been reversed; the nerves for a long while remain white while the surrounding fat becomes black. Painting with corrosive sublimate, after the osmic is washed off with distilled water, increases the contrast.

A large tangled plexus of nerves issues from a ganglion (*semilunar ganglion*) over the aorta, above the renal vessels (pl. I. fig. 7); the fibres run along the bloodvessels of the neighbourhood, forming minor plexuses. Those with which we are chiefly concerned accompany the splenic and renal vessels; from these minor plexuses, numerous offshoots are given to the corresponding splenic and renal groups of glands. In many cases a plexus is formed around the gland, in others fine fibres may be traced into the substance of the capsule. Other fibres proceed from the ganglion more directly, while in the case of the splenic group, several fibres arise from the solar plexus itself (or more correctly from that portion of the plexus lying on the aorta anterior to the ganglion).

Several attempts have been made to display the nerve supply to the interior of the gland, using the gold chloride and formic acid method of Löwit. I can at present only state that the capsule has an abundant nerve supply, the fine nervous fibrils breaking up in this tissue and in the trabeculae, and ending in delicate twigs, to which are occasionally attached small angular enlargements.

The nerve supply of the organs under consideration is so abundant, as to lead to the conclusion, that a considerable influence must be exercised by the nervous system, probably in close connection with the changes taking place in the glands. Stimulation of the gland itself or of the nerves supplying it, in the living animal, causes slight but distinct paling of the red patches representing the sinuses, while at the same time the whole gland suffers a slight diminution in bulk.

[1]) Archives de Zoologie expér. et gén. 2e serie. tome V. bis. 1887. Supplémentaire.

These observations are based on direct naked eye appearances only.[1]) The changes seem to be very similar to those taking place in the spleen when similarly stimulated, and are probably brought about by contraction of the abundant involuntary muscle fibres in capsule and trabeculae. No rhythmical contractions have been observed in any glands.

IX. Lymphatic supply.

In the glands of the rat I have failed to find any definite lymphatic vessels of any sort; the same observation applies to hæmal glands generally.

In the hæmal lymphatic glands of the cat, dog, and ferret, there is no difficulty in finding large vessels containing nothing but lymph corpuscles in many parts of the organ. The method adopted for tracing the vessels was as follows: A cat was fed on a fatty diet including milk, and a few hours afterwards killed and quickly opened. The lymphatic vessels were charged with white chyle, and many were traced to the glands at different points. Sometimes as many as six to ten of these afferent vessels pierced the capsule, while one large efferent vessel led away from it. Such a gland was quickly excised and fixed and hardened in Flemming's solution or osmic acid. The chyle was thus stained black, wherever present in the gland, and formed a natural injection, by which the lymphatic circulation could be ascertained. Sections of the gland showed the sinuses stained black in many places, indicating that the chyle stream has a direct connection with them. When preparations of the corresponding glands were made by other methods these sinuses were seen to contain many blood corpuscles, so that one can but conclude that in the sinuses there is a mixture of blood and lymph.

X. An account of Phagocytosis in the hæmolymph series of glands.

1. The phenomena of Phagocytosis.

The process of phagocytosis is remarkably well seen, in all its stages, in the hæmal glands of the rat; the most satisfactory results

[1]) The difficulties of obtaining graphic records of such changes are obvious.

are to be obtained by staining sections of these glands in hæmalum and eosin, on account of the well known attraction of red cells for eosin. This method gives a bright contrast between the red cells, the blue of the hæmalum and the yellow of the pigment.

I have attempted in my figures (pl. I. fig. 11) to give typical illustrations of the process of phagocytosis; all the stages with the exception of one (pl. I. fig. 11 *d*) were drawn from the same slide.

Vincent and Harrison[1]) first suggested that, in the hæmal glands, a phagocyte, by a method similar to that adopted by an amœba in feeding, may ingest several (as many as 20) erythrocytes. They supposed that the ingested cells are subsequently attacked, and eventually transformed into the pigment, which they found both in the cells and free in the sinuses.

Schumacher's[2]) description was more detailed. He observed a vacuolation, not only in the phagocyte, but in the ingested red cells themselves. The vacuoles of each erythrocyte, he described as running together, so that ultimately a single vacuole remained, of the shape and size of an erythrocyte. I am unable to confirm these observations of Schumacher. In cover glass preparations vacuoles certainly abound, but such a preparation is not altogether satisfactory, as the mere drying of the film, or the friction produced by the cover glass, is quite sufficient to produce appearances easily mistaken for vacuoles: in fact many other specimens prepared by this method show a distinct vacuolation in many cells, though such is not normally the appearance. In sections, however, vacuoles do certainly exist, but these have only been observed, with very few exceptions, in the interior of cells containing little or no pigment. Moreover in these vacuoles are frequently seen unaltered blood corpuscles (pl. I. fig. 11 *c*). I consider the vacuolation due to the fact that where one or more blood cells are engulfed by the psuedopodia of a phagocyte (assuming that it ingests erythrocytes or other food particles after the manner of an

[1]) Loc. cit.

[2]) Loc. cit. It is to be remembered that Schumacher described phagocytosis in "Lymphdrüsen" and apparently was unacquainted with any special form of the glands such as hæmal or hæmal lymphatic.

amœba), a considerable quantity of plasma is taken in with them, giving rise to the appearance in section of red cells lying in an empty space. I cannot agree with Schumacher that vacuolation is characteristic of certain phases in the *destruction* of an erythrocyte.

On a careful examination of a number of eosin stained sections, I have observed that many small red masses occur in the interior of phagocytes or giant cells. *These are of two varieties.* The one variety consists of oval pale bodies of the shape and size of red blood corpuscles, staining of the same depth of tint, or perhaps lees deeply than the erythrocytes found in the surrounding sinus (pl. I. fig. 11 *d.e.f*): these are freshly ingested blood cells, of which there may be from one to twenty in the interior of a single phagocyte (pl. I. fig. 11 *d*), and one or more are often seen lying in a clear space, which may be termed a vacuole (pl. I. fig. 11 *c*). A second variety of eosin stained body is more conspicuous. They are more brightly stained, and are usually spherical. They are more highly refractive and vary in size from very minute globules to rounded masses twice the size of a blood corpuscle (pl. I. fig. 11 *g.h.j*). They are, I consider, masses of hæmoglobin. The appearances seen in sections have led me to perform some comparative experiments on the staining power of equal portions of ordinary defibrinated and laked blood. The results of these experiments point to one of two conclusions: either that the cell wall of an erythrocyte is not easily permeated by eosin, or that hæmoglobin forms with a constituent of the cell protoplasm a compound which has a weaker affinity for eosin, than hæmoglobin itself.

The first action of a phagocyte upon a red cell is probably therefore in the direction of liberating its contents, either by absorption or rupture of the cell membrane; in either the result is the formation of a spherical mass of hæmoglobin. Several globules of hæmoglobin may run together to form a larger mass, or, as more frequently occurs, some of the original globules break up into several smaller ones, any of which may take on the spherical form. The more lightly stained masses, which are probably unaltered erythrocytes, show considerable constancy in shape and size.

It is not unlikely that worn out or damaged cells, and not heal-

thy individuals are destroyed by the phagocyte; and *it is further possible that the first stage in the disintegration may occur in the blood stream.*

I now pass on to the further changes which occur in phagocytosis. In many giant cells yellow *masses of pigment are observed, of the dimensions of an erythrocyte, and moreover many intermediate forms between the darkly stained spherical red bodies, and these masses of pigment.* Thus rounded masses are present which consist of two zones, centrally of the dark highly refractive red, and peripherally of bright yellow. The inner zone is irregular in outline, and the yellow zone surrounding it has every appearance of eating its way into it (pl. I. fig. 11 *i.k*); between the two layers minute black granules are often apparent, of the nature of which it is impossible to speak definitely, though they are probably some intermediate form of pigment such as hæmatin. In some cases the yellow zone is increased at the expense of the red, in other cases there is but a thin yellow zone surrounding a larger red area; yet again there are yellow bodies with a tinge of red spreading from the centre (pl. I. fig. 11 *h.i*). In all cases, when present, the red zone is of the dark highly refractive red colour.

Such bodies as have just been described, can only be regarded as intermediate stages in the transformation of masses of hæmoglobin into masses of pigment.

Many observers have stated that pigment, in large quantities, is found lying free in the blood sinuses of these glands, but I am unable to confirm this statement. Only very small quantities have occasionally been seen in a free state in this situation. The yellow pigment is almost invariably enclosed in large amœboid cells, while in the sinuses. In some cases it is present in such quantities as to obscure the nucleus (pl. I. fig. 11 *l* and pl. I. fig. 9 *ph. 3*): this may possibly account for the view of previous observers that such pigment is free.

It is very strikingly apparent in all my preparations that whereas the pigment in the cells of the sinus is usually finely granular, large quantities are found in the adenoid tissue in the neighbourhood of the sinuses which is of a darker tint, often dark brown, consequent upon its collection into these larger masses (pl. I. fig. 8). In this situation

the contents of many broken down phagocytes have apparantly run together to form large spherical aggregations, often many times the size of a phagocyte. These are presumably free, though in the case of many of the smaller masses, a thin cell wall may be observed surrounding a globular mass of pigment, and occasionally a nucleus is to be seen. It is extremely likely in view of these facts, that after red cells have been completely converted into pigment, either into pigment masses of the same size, or into a number of minute masses or granules of smaller size, that these masses tend to run together, owing to increased pressure in the cell, and form larger masses. When a phagocyte has reached this stage and is overloaded with pigment, it is no longer serviceable in the sinus and wanders away to the adenoid tissue. Probably the adenoid tissue is reached through such capillaries as are illustrated by fig. 5 *c.a*, in which phagocytes overladen with pigment are often found. Reaching the adenoid tissue the pigment is liberated, simultaneous with the death of the phagocyte, which could not possibly be restored to its original form. The pigment thus freed runs together into the large masses already described, and leaves the glands by the small veins communicating with the capillaries just mentioned.

Schumacher described in his first paper certain rod shaped enclosures within the phagocytes, in his last contribution he stated that he had not observed them with such frequency after the publication of his first article; I have only very occasionally observed such appearances. The same observer described leucocytes within the giant cells, though he did not lay much stress on the observation. In this I am able entirely to confirm him, and had indeed observed them before seeing his paper (pl. I. fig. 11 *j*). They occur with considerable frequency in some glands, *particularly in hæmal lymphatic glands*, and it is often possible to make out stages in their disintegration (pl. I. fig. 11 *k*). When first seen they give the phagocyte the appearance of possessing two nuclei, but on closer inspection a difference in staining reaction between the two nuclei is noticeable, the smaller nucleus closely resembling a cell such as is found in the lymphoid tissue. It is probable that this form of destruction of leucocytes occurs

in certain glands, especially those richly supplied with lymph, to a far larger extent than is at present suspected, as the process is much more difficult to detect than erythrocyte disintegration. The process of breaking down the leucocyte seems to consist essentially in its solution; the nucleus may be split up, or a giant cell may be found containing irregular bodies, staining a light blue tint, which are in all probability the remains of leucocyte nuclei.

For some time there was difficulty in finding a phagocyte containing no red corpuscles or pigment; in other words a young giant cell. In many sections, however there are to be seen large clear "*hyaline*" cells, the protoplasm of which stains a light blue or violet with hæmalum (pl. I. fig. 11 *a* and pl. I. fig. 9 *l.h.c*), these cells are usually of the same size as a phagocyte and occasionally contain blood cells enclosed in vacuoles (pl. I. fig. 11 *c*). Mitosis is also frequently seen going on in them (pl. I. fig. 11 *b*). The difference between such a cell and one of those filled with pigment and blood corpuscles is so striking that they are easily mistaken for different varieties of cells: it seems very probable that they are phagocytes, either newly developed or in an inactive condition.

2. Glands in which Phagocytosis occurs.

Up to the present time, the extent to which phagocytes, or giant cells capable of destroying erythrocytes, are distributed throughout the hæmolymph organs of vertebrates has not been fully realised. They have been described in the spleen by Kölliker, as already noted; in the hæmal glands of the rat by Vincent and Harrison; in certain lymph glands in monkeys by Schumacher; and in the hæmal lymphatic glands of dogs by Drummond. *I have not failed to find signs of phagocytosis proceeding in the hæmal or hæmal lymphatic glands of any Mammal examined.* In the glands of man, monkey, ox, sheep

[1]) In fresh preparations Schumacher has failed to observe actual phagocytosis proceeding, though he has noticed slow amœboid movements of the giant cells. I have several times watched phagocytes on the warm stage, but have never seen the ingestion of red cells. I have also placed amœbæ in a highly dilute saline solution containing erythrocytes but never observed even the ingestion of the blood corpuscles by the amœbæ.

and horse, occasional cells containing erythrocytes occur, and also scattered masses of pigment. In the hæmal lymphatic glands of the dog, cat, ferret, stoat and weasel, phagocytes crammed with red blood cells are frequent. In the rabbit and rat, the process is so active that the sinuses are usually literally packed with phagocytes. In the pig and guinea pig though I cannot be certain of having seen these giant cells, yet small masses of pigment are occasionally scattered over the sections.

In birds the only glands examined have been those of the fowl, and in these abundant signs of phagocytosis have been observed.

The process however is not confined to these glands; it is occasionally found in ordinary lymphatic glands, especially in those of the rat and rabbit, less frequently in those of the sheep. It is difficult to understand how the blood reaches the lymph sinuses in ordinary lymphatic glands, unless indeed some communication exists between these spaces and the blood capillaries. In the case of certain glands in which the blood vessels have been injected, the gelatin mass has occasionally been noticed in the sinuses; whether this is due to such a communication, or to breaking down of the delicate capillary walls, I am not prepared to say.[1])

3. Origin of Phagocytes.

Three views have been held as to the origin of phagocytes found in hæmolymphatic structures. Of these the first advanced was that of Schumacher, which supposed the phagocyte to be developed from a reticulum cell. This view, which has lately been supported by Weidenreich, breaks down if the idea that the reticulum is composed of fibrous tissue and not branched cells, is accepted. Schumacher considered that the reticulum is composed of branched cells, and advanced the following evidence in support of the theory that they give origin to phagocytes.

He stated that different phases occur in the glands of monkeys: that in one gland, great abundance of reticulum and few phagocytes

[1]) Another explanation, namely that such glands are low types of hæmal lymphatic glands, might be offered.

are present, while in others little reticulum but numerous phagocytes are found.

In other glands he has observed many phagocytes, some spherical, others shewing clear branched processes, which were in many cases directly continuous with similar processes of reticulum cells.

I am unable to entirely confirm this view of the origin of phagocytes, for as is now recognised, reticulum consists of fibres and not branched cells. Also, even if the reticulum were composed of branched cells, the loss of these, when they were developed into phagocytes, would leave the adenoid tissue almost entirely unsupported. It is much more probable that the processes observed by Schumacher were those of "endothelium cells attached to the reticulum" and that these cells give origin to phagocytes. The second view has been advanced by Thomé [1]), who believes that endothelium cells lining the capillaries are developed into giant cells with phagocytic properties. He has observed certain intermediate forms between endothelium cells of the capillaries and phagocytes. The third view has been suggested by Drummond [2]) who believes the cells are nothing more than enlarged leucocytes. He has found a complete series of intermediate forms between ordinary leucocytes and the hyaline cells under discussion. In one respect I am able to confirm Drummond, in that certain of the intermediate forms he described have been observed, such as smaller hyaline cells, and leucocytes having more than the usual amount of protoplasm surrounding them. But this is not sufficient evidence in support of the theory, though it is certainly somewhat comparable to the statement by Köllicker [3]), that ordinary leucocytes in the spleen grow, by feeding upon red cells, into giant cells or phagocytes. There is no reason however why this view should be abandoned, or indeed why all three processes should not proceed side by side. I am inclined to the view that *the endothelium lining the reticulum, capsule, adenoid tissue and capillaries is continuous, and think it highly probably that phagocytes may be developed from any or all of its cells.* In a hæmal gland from an ox, I have observed endothelial cells, containing the characteristic pigment, covering

---

[1]) Loc. cit. [2]) Loc. cit. [3]) Loc. cit.

the trabeculae (pl. II. fig. 15), and also other irregular cells, similarly filled, in close connection with reticulum fibres. In one cell, drawn in the figure, and which was more swollen than the remainder, an enclosed erythrocyte was observed, and this large cell was continuous by means of a protoplasmic process with the endothelial lining of a trabecular strand. It is also certain that in some glands, where phagocytes are especially numerous, the reticulum seems considerably reduced, though the actual reticulum fibres, which often stain but lightly, are not scarcer, *but rather the endothelium or "reticulum cells" usually attached to them are absent.* Nothing has been observed suggesting the origin of phagocytes from the endothelium of capillaries *but it is probable that endothelial cells in other situations are capable of developing into cells with blood destroying properties.* The question cannot be definitely settled until a really good series of intermediate forms between such an endothelium cell and a phagocyte has been observed.

In discussing the origin of the cells under consideration Schumacher has described an appearance to which he gives the name "Zwischengewebe". This he found in the sinus, in the neighbourhood of the capsule, consisting of densely packed phagocytes, which were so closely pressed together as to occasionally assume hexagonal outlines; in these cells he described the process of mitosis as actively proceeding, believing such groups of cells to be the situation in which the phagocytes of the gland, generally, have their origin. Structures somewhat resembling these appearances certainly exist in some of the glands of the rat, but by no means frequently, and I am not convinced that they represent the only or even the chief position in which phagocytes have their origin.

4. Nature of the pigment found in the glands.

A general misconception has arisen in regard to the extent to which the breaking down of the blood pigment may proceed in hæmolymph glands. It is surprising to find the statement by Halliburton[1]), that the spleen cells do not proceed so far as to liberate hæmoglobin from the corpuscles. If *this* change does not occur, what possible

[1]) Essentials of Chemical Physiology. 1899.

destructive effect can the spleen have upon blood corpuscles? The argument, advanced against the breaking down of red cells, is that no free hæmoglobin is found in the splenic vein; this statement may or may not be correct, *but in a small vein of the spleen, I have observed quantities of the bright yellow pigment*, so characteristic of blood destruction.

In the glands with which we are more particularly concerned at present, pigment is found in abundance in the sinuses and adenoid tissue, varying in colour from a bright golden yellow, to a deep orange or brown, according to the density of its accumulation. Drummond and Warthin have both noticed the presence of free iron in the glands, though the last observer has given no account of the methods which he employed in identifying it. Drummond employed the potassium ferrocyanide and hydrochloric acid method. I have used both this method and that of Macallum, which consists in soaking alcohol hardened sections for a few minutes in a dilute solution (1 in 300) of hæmatoxylin. Free iron particles are stained an intense black. Sections so treated show small black granules similar to those seen in liver cells, within the phagocytes and on the borders of the adenoid tissue. It is probable that much of the hæmoglobin of disintegrated erythrocytes is completely reduced to an iron free pigment.

There seems no reason to doubt that the process of blood destruction in the spleen is identical with that in hæmolymph glands generally.

The problem, as to the precise nature of the pigment, is harder to solve. Vincent and Harrison considered it to be some form of hæmatin. As the substance is embedded either in the adenoid tissue or in the phagocytes, microchemical tests are to large degree unsatisfactory. In experiments on teased preparations, it has been found that the pigment is, to a considerable extent, soluble in alkalies; solutions of sufficient concentration, show, on spectroscopic examination, absorption in the red and violet, but no bands are apparent. Further, in many cases, the addition of a fuming concentrated solution of nitric acid caused the appearance of a faint green coloration (Gmelin's test). I am inclined to regard the pigment as closely allied to bilirubin, if not, identical with it. There is no reason, to doubt the capability

of the spleen and other hæmolymph glands, to so reduce hæmoglobin to iron free compounds. Latschenberger[1]) found that, twelve hours after the injection of defibrated blood subcutaneously, in the horse, the tissues contained a substance in flakes *varying in colour from dark orange to bright yellow, composed of small spherical masses, about a quarter the size of red corpuscles, which gave Gmelin's reaction readily.* It is highly probable that the pigment present in hæmolymph glands is identical with that found by Latschenberger.

5. *Relative degree of activity, as regards Phagocytosis, of the spleen and hæmal glands of the rat.*

The hæmal glands of certain animals are so conspicuous, that a comparison of their united weight, with that of the spleen and that of the whole body, is of interest.

I was at first inclined to regard the function of hæmal glands as subsidiary to that of the spleen, but after an examination of numerous sections of the latter organ, I believe that the process of blood destruction occurs in the hæmal glands, of the rat at all events, to an extent exceeding the similar process in the spleen. Vincent and Harrison noticed the similarity, between the process occuring in the two varieties of organ; they are more than similar, *they are identical,* and the above description of the phenomena of phagocytosis will apply equally to the spleen or hæmal glands.

Whereas only a few scattered phagocytes are found in the spleen, these cells form *the most conspicuous cells in the hæmal glands of the rat,* and I am of opinion, although estimates of this kind can naturally be but approximate, that blood destruction proceeds, to a far larger extent, in a single hæmal gland in the rat than in the entire spleen. When it is considered that often as many as 10—15 such glands may be found in a rat, the extreme importance of these glands, as destroyers of blood, can no longer be doubted.

The following is the result of a number of estimations of the weight of the hæmal glands, compared with that of the spleen and body weight:

[1]) Monatsh. f. Chem. Wien 1888. Bd. IX. S. 52; Sitzungsber. d. k. Akad. d. Wissensch. Wien 1888. Bd. XLVII. Abt. 2b. S. 15.

Average weight of body	185	grammes,
Average weight of spleen . . .	0,702	grammes,
Average weight of glands . . .	0,081	grammes.

These results apply to the tame rat only, the weight of the glands in the wild rat is very much increased proportionately, even as much as three or four times.

I have been unable to find any relation between the total weight of the glands and that of the spleen in different rats. For example in the case of an abnormally small spleen, the hæmal glands showed no signs of enlargement, as would certainly be expected if the function of hæmal glands was subsidiary to that of the spleen. The evidence given by the experiments of Vincent [*17*c] is in accordance with these observations: in a number of Splenectomy experiments upon dogs, he was unable to dedect any hypertrophy of the hæmal lymphatic glands, even after a period of eighteen months; nor was there any appreciably increased phagocytosis apparent in any of these glands.

XI. Function of the hæmolymph organs.

The result of the present investigation has been to further confirm the view as to the blood destroying powers of hæmolymph glands, and to show that the process is more widespread than has as yet been suspected. It has also resulted in the conclusion that the processes are identical in the spleen, hæmal, hæmal lymphatic and lymphatic glands.[1])

Another undoubted function of all the members of the series, is the elaboration of white corpuscles. This process proceeds in the germ centres, in which stages of active karyokinetic division may be frequently observed. Mitosis also occurs in the general lymphoid tissue, where nuclear figures are often seen.

The glands have a further minor function, namely the destruction of leucocytes. This occurs by phagocytosis in many glands, but particularly in those organs which are abundantly supplied by lymph. Disintegration also takes place in another form. Schumacher has ob-

[1]) If such processes take place in lymphatic glands, which is extremely doubtful.

served masses, having a homogenous structure, in the lymphoid tissue, in which he considers such degeneration is probable, believing that it takes place in a manner similar to that occuring in connective tissue.

Warthin has suggested a fourth function, the elaboration of red cells. The appearances described have been noticed in the case of the spleen only. The function may be as he suggests pathological, or peculiar to the glands of the human subject.

A cyclic function has been attributed to the hæmal glands by several observers; the view has been based on the fact that different appearances have been noticed at different times in glands taken from the same positions, giving an indication of different phases of activity. Such changes are particularly noticeable in the glands of the rat, though they also occur to a minor extent in many other animals. The glands, in the rat, possess a very thin transparent capsule, consequently the nature of the contents of the sinuses may be judged by external appearances: thus they are sometimes brown, sometimes red. Sections of such glands show, in the first case, the sinuses filled with phagocytes containing pigment; little or no blood is present, and the reticulum is indistinct (probably owing to the liberation of endothelial cells). In the second case, the sinuses are seen to be filled with blood, only a few phagocytes are present and the reticulum is conspicuous. Intermediate stages are found, the glands having to the naked eye a mottled red and brown appearance while in sections the sinuses are observed to contain a number of phagocytes and red blood corpuscles.

These appearances would seem to be due to the setting free of a number of phagocytes "*en masse*", into a blood-filled sinus. These cells rapidly ingest the bulk of the erythrocytes present and convert them into pigment. The pigment is set free in the adenoid tissue and is found in this situation in large quantities, especially in those glands which have their sinuses filled with blood. The wandering of the phagocytes to the adenoid tissue would leave the sinuses empty, and this may account for the "collapsed" glands occasionally met with. Presumably the collapsed gland is once more distended with blood,

and the remaining endothelium cells again proliferate, liberating a new batch of phagocytes, with the commencement of a new cycle.

As to the length of the various phases of such a cycle, nothing is definitely known, but it is probable that the stage in which pigment abounds in the sinuses is of longer duration than that in which they are filled with blood. The following statistics seem to indicate that this first stage is approximately double the length of the second.

No. of rats examined	46.
„ „ brown renal glands found	59.
„ „ red renal glands found	32.

Experimental work in this direction might be done with advantage. For instance a living rat might be opened from time to time and the colour of the organs noticed. Such an experiment would be interesting as furnishing evidence of the time taken by a phagocyte to destroy a blood cell.

If the above appearances may be construed as indicating a cyclic function of the organs it is probable that they occur throughout all the glands of the body simultaneously, as it is usually found, that if one of the organs has a brown colour, the remainder will also have the same tint.

XII. Development.

The development of the hæmal glands has as yet received little attention. So far as I know no work has been done in this direction, and a discussion without such investigation is of little value. Vincent and Harrison[1]) considered that they were modified lymphatic glands, and probably developed from these. Drummond[2]) differed from these observers on two grounds; first that hæmal glands have not the same distribution as ordinary lymphatic glands; and secondly that they are seen at a comparatively early stage in the embryo. He describes the development of the lymphatic system and the adenoid tissue of lymphatic glands, and considers that in the earliest stages the development of the hæmal glands may run parallel to that of the true lymphatic

[1]) Loc. cit. — [2]) Loc. cit.

glands. He has found typical hæmal glands in a fœtal calf measuring 9 inches, which were in diameter from · 5 to · 75 mm.

As to the first objection brought forward against the view that they are developed from ordinary lymphatic glands, I cannot agree with Drummond in his opinion that hæmal glands have not a very similar distribution to ordinary lymphatic glands. In the Ungulata the two varieties are found together in all situations within the body and chest cavities. In rats the general arrangement is certainly very constant, but so also is the distribution of ordinary lymphatic glands. Further, in the only case in which I have observed a renal hæmal gland absent in the rat, it was replaced by a lymphatic gland.

In a human fœtus 5 months old, I have found two small renal glands, which were undoubtedly hæmal glands, though too macerated for histological examination. It has also been noticed, that in rats, the older the rat, the more characteristic is the gland: in the youngest rats, glands containing but a very small proportion of sinus occur, and in still younger ones, or in embryos before birth, structures containing no blood sinuses are often present. In this animal the sinuses seem to appear and develope as the animal grows.[1])

There is no direct evidence that hæmal glands are developed in the individual from ordinary lymphatic glands, though we may conceive of their having been phylogenetically so derived.

XIII. On the structural inter-relationship of the various members of the hæmolymph series.

It is necessary, before entering upon a comparison of the different members of the hæmolymph series, that a short description should be given of the structure of the spleen, as it has been interpreted after the examination of a number of specimens. The previous literature on the subject is so extensive, that it cannot here be fully considered. It is only essential to briefly summarize the accounts

[1]) In a pup, less than one week old, recently examined, very numerous glands were found. They were present in larger numbers than in the adult, and their sinuses appeared larger. They have not yet been histologically examined.

of three recent observers, dealing chiefly with those points having the closest bearing upon the present subject.

In many text books, as in that of Böhm und Davidoff[1]), it is stated that the vascular system of the spleen is open; that is to say, that many small capillaries open directly into what is termed the "spleen pulp", and that veins commencing in a similar fashion, by direct continuity with the interior of the pulp spaces, form the channel by which the blood is drained away.

Kölliker [*9* a], after a number of experiments, in which he made careful injections of the arteries and veins, under different pressures, concludes that the vascular system is closed, or in other words that the blood never leaves the vascular channels. He believes, that injections passing into the pulp space, are extravasations, for delicate injections do not enter the spleen pulp, which consists of a string like arrangement, filling up the spaces between the blood vessels, the veins in particular.

Weidenreich [*19* a] believes in both open and closed systems, occurring side by side; that there is an arterial supply directly continuous with a venous supply by capillaries; while there are in addition arteries and veins, which have direct communication with the spleen pulp.[2])

My investigations lead me to a view hardly agreeing with any of those above quoted. In the first place *the Malpighian corpuscles of the spleen may in many cases be seen to be enclosed in a very definite endothelium* (pl. II. fig. 16), which in all its features resembles that covering the adenoid tissue of a hæmal gland. The spleen pulp may be regarded simply as a large sinus, traversed by an exceedingly dense reticulum and by many trabeculae, which conduct the blood vessels through it. It is true that small capillaries open into the spleen pulp, or rather into this sinus, and that small veins conduct the blood directly away from it. The reticulum of the spleen is composed, as

---

[1]) Loc. cit.

[2]) Weidenreich also refers to the homology between the spleen pulp and the sinus of a "hæmolymph" gland. This has been noticed by several previous observers.

in the case of hæmal glands generally, of a fibrous meshwork, *lined throughout by a definite endothelium, which forms a layer more or less continuous with the endothelium covering the Malpighian corpuscles.* This arrangement is such that when the blood leaves the capillaries or small arteries entering the spleen pulp, it passes into spaces lined, by endothelium, *which together form a large sinus in every way comparable to that of the typical hæmal glands of the sheep or ox*, although in the spleen the reticulum is denser. The endothelium of the small arteries and veins entering or leaving the spleen is continuous with the endothelium of the reticulum, though the cells of the latter are to a great extent modified to suit their surroundings. The application of an endothelial cell to an irregular fibrous structure, such as reticulum, must necessarily distort it considerably, and when sections are taken through such an endothelial-lined reticulum, it may often appear to be composed of irregular or branched cells. The blood stream consequently remains in closed spaces, and has little or no contact with adenoid tissue or reticulum, except in the case of the absence of an endothelial cell, which may in many cases be due to its having assumed phagocytic functions.

As regards the inter-relationships of the different glands under discussion, the general arrangement of the adenoid tissue and sinus forms the first point of consideration. Adenoid tissue exists in each individual of the hæmolymph series, from the lymphatic gland to the spleen, but it is more abundant in the former and least in the latter (pl. II. fig. 17—20). In the lymphatic glands almost the entire organ is made up of this tissue, broken up considerably by the comparatively small lymphatic sinuses which pervade it (pl. I. fig. 4 and pl. II. fig. 17). In the hæmal lymphatic gland (pl. I. fig. 3 and pl. II. fig. 18), there is always a large sinus, usually centrally placed. There are in addition peripheral sinuses connected with the central sinus by numerous smaller blood-lymph spaces, which are extremely subdivided. In the hæmal gland of the sheep the peripheral sinus occupies more than half the area of section, and has smaller sinuses in connection with it (pl. I. fig. 2 and pl. II. fig. 19). In the spleen (pl. I. fig. 1 and pl. II. fig. 20), *the sinus forms the chief part of the gland;* and the Malpighian cor-

puscles are the sole representations of the lymphoid masses of other members of the series, which elaborate white corpuscles. Furthermore, in such masses large arteries usually exist; thus they are found in the lymphoid masses of lymphatic and hæmal lymphatic glands; in the hæmal gland they occur in strands of adenoid tissue in every way comparable to the spherical Malpighian corpuscles of the spleen, which are almost always found to contain small blood vessels coursing through them.

Endothelium and reticulum are common to all the organs and have an identical arrangement in each. The reticulum and trabeculae become more numerous as one ascends the series to the spleen, in which they are particularly dense. This is but natural, as one of the chief functions of reticulum and trabeculae is their supporting property, for they hold the lymphoid tissue in place in the centre of the sinuses; accordingly they are most plentiful in the organ having the widest sinus.

Further points of resemblance between the members of the series are found in their functions. It is probable that in almost all blood destruction and elaboration of white cells proceeds.

The chief differences of importance between the various hæmolymph glands, lie in their vascular and lymphatic supply. This has already been referred to in previous paragraphs as depending on the relative quantities of the fluids, blood or lymph, supplied to the organs. Thus whereas the lymphatic ducts to the spleen (pl. II. fig. 20) are probably confined to the walls of the blood vessels and the Malpighian corpuscles, blood enters freely into the sinus (spleen pulp). On the other hand the vascular supply of lymphatic glands is comparatively small (pl. II. fig. 17) and it is not yet ascertained that there is any communication between this blood supply and the lymphatic sinuses, which are in connection with large lymph vessels. Between these extremes intermediate forms are found including the hæmal lymphatic gland which has an abundant blood and lymph supply.

From this account it will be seen that a complete series of hæmolymph organs exists, which may be classified in the order: *spleen*, *hæmal gland*, *hæmal lymphatic gland*, and *lymphatic gland*.

XIV. Summary of chief Conclusions.

The following points are either new, or have not yet been sufficiently emphasised by previous observers.

1. It is probable that in addition to the spleen, glands which may be placed in the category of "*hæmal*" or "*hæmal lymphatic*" are universally present in *Mammalia*. Comparable structures occur also in *Aves* and *Pisces*. In Mammalia there is a definite distribution of the different varieties of hæmolymph glands throughout the several natural orders examined. Thus *typical* hæmal glands appear to be restricted to the *Primates* and *Ungulata*, while in *Carnivora* hæmal lymphatic glands only are present.

2. The hæmal and hæmal lymphatic glands are distributed with considerable degree of constancy in three main groups, *renal*, *splenic* and *subvertebral*.

3. The blood or blood lymph spaces of these glands are traversed by a fibrous reticulum, forming a network of spaces lined by cells commonly called "reticulum cells", which form a continuous layer with the typical endothelial cells bounding the sinus, and lining the vessels entering or leaving it.

4. In the modified hæmal glands of the rat, small arteries open directly into the sinuses, while veins proceed from the sinuses and appear to have direct communication with them, being strongly guarded by valves.

5. The glands in the rat and dog have been observed to have an abundant nervous supply from the sympathetic. Stimulation of the nerves, or gland itself, causes slight but definite paling of the organ, and a diminution in size.

6. In the *hæmal lymphatic glands*, the blood and lymph streams meet, and to a great extent mix.[1])

7. *Hæmal glands*, inclusive of spleen, and hæmal lymphatic glands are centres for the destruction of the blood elements both red and

[1]) This may account for the abundant presence of blood in the lymph, flowing from the thoracic duct, in cases where the inferior vena cava has been clamped with the object of raising the blood pressure in the abdominal capillaries. (Starling, Schäfer's Text Book of Physiology. 1901.)

white. Glands falling under the heading of ordinary lymphatic glands may have the same function to a slight degree. This takes place by a process of phagocytosis, identical in all. The process as applied to an erythrocyte is briefly as follows: A red cell is ingested by a phagocyte, and the cell contents are first liberated: the globular mass of hæmoglobin is transformed into granules of bright yellow pigment, by a gradual process, extending from the periphery to the centre of the globule. The final product appears to be a substance allied to bilirubin, and is liberated in the adenoid tissue.

8. In the rat the lower members of the hæmolymph series are, in proportion to their size (if not absolutely), more important as destroyers of erythrocytes, than the spleen.

9. The phagocytes are probably derived from any of the endothelial cells attached to the wall of the sinus or meshes of the reticulum. It is not impossible that still others may be transformed varieties of leucocytes.

10. The hæmolymph glands form structurally an almost unbroken series of organs, the simplest or least differentiated being the *ordinary lymphatic glands*, while the most highly differentiated is the *spleen*. Between these extremes are found structures of every possible graduation, including *hæmal lymphatic glands*, *hæmal glands*, and *accessory spleens*. The spleen pulp is not only homologous with the sinus of the lower members of the series, but structurally is almost identical with it.

This sinus is marked off from the adenoid tissue represented by the Malpighian corpuscles, by a definite endothelium, in every way comparable to that found in typical hæmal glands.

XV. Bibliography.

1. Balfour, The pronephros of Teleostians and Ganoids. Brit. Assoc. Reports 1881. p. 721.
2. Böhm und Davidoff, Lehrbuch der Histologie des Menschen. 2. Aufl. 1898.
3. Clarkson, a) Report on hæmal glands. British Medical Journal. July 1891. p. 183. — b) Text book of Histology. 1896.
4. Drummond, On the structure and functions of the hæmolymph glands. The Journal of Anatomy and Physiology. Jan. 1900. Vol. XXXIV. p. 198.
5. Gibbs, H., a) On some structures found in the connective tissue between the renal artery and vein. Quart. Journ. of Micr. Sc. 1884. Vol. XXIV. p. 186. — b) American Journal of Medical Sciences. 1893.
6. Höhl, E., Zur Histology des adenoiden Gewebes. Archiv f. Anat. u. Phys. Anat. Abteilung. 1897. S. 133.
7. Hoyer, H., Beiträge zur Kenntnis der Lymphdrüsen. Archiv f. mikr. Anat. 1889. Bd. XXXIV.
8. Kanthack and Hardy, Morphology and Distribution of the wandering cells of Mammalia. Journal of Physiology. 1894—95. Vol. XVII. p. 82.
9. Kölliker, a) Handbuch der Gewebelehre des Menschen. 6. Aufl. b) Mitteil. d. Züricher Nat. Ges. 1847. S. 120.
10. Leydig, Lehrbuch der Histologie der Menschen und der Tiere. 1857.
11. Minot, On a hitherto unrecognised form of blood circulation without capillaries in the organs of vertebrates. Proc. of the Boston Society of Natural History. 1900. Vol. XXIX. p. 185.
12. Robertson, W. F., Lancet. Nov. 1890.
13. Saltykow, Ueber bluthaltige Lymphdrüsen beim Menschen. Zeitschr. f. Heilkunde. 1900.
14. Schumacher, a) Ueber die Lymphdrüsen des Macacus rhesus. Archiv f. mikr. Anat. 1897. Bd. XLVIII. S. 145. — b) Ueber Phagocytose und die Abfuhrwege der Leucocyten in den Lymphdrüsen. Ibid. 1899. Bd. LIV. S. 311.
15. Thomé, Endothelien als Phagocyten (aus den Lymphdrüsen von Macacus cynomolgus). Ibid. 1898. Bd. LII. S. 820.
16. Vincent and Harrison, On the hæmolymph glands of some vertebrates. Journal of Anatomy and Physiology. Jan. 1897.

17. Vincent, S., a) Contributions to the comparative anatomy and histology of the suprarenal capsules etc. Transactions of the Zoological Society of London. 1897. Vol. XIV. Part III. — b) On hæmolymph and hæmal lymphatic glands. Proc. of Physiol. Society. Feb. 12. 1898. Journ. of Physiol. March 1898. Vol. XXII. No. 5. p. 40. — c) The question as to alterations in the lymphatic and hæmal glands after removal of the spleen. Proc. of Physiol. Society. Decr. 9. 1899. Journal of Physiol. April 1900. Vol. XXV. No. 4. p. 2.

18. Warthin, a) Journal of Boston Society of Medical Sciences. April 1901. — b) Journal of Medical Research. July 1901. — c) American Journal of Anatomy. Nov. 1901.

19. Weidenreich, a) Das Gefässsystem der menschlichen Milz. Archiv f. mikr. Anat. 1901. Bd. LVIII. No. 2. S. 247. — b) Ueber Blutlymphdrüsen; die Bedeutung der eosinophilen Leucocyten. Ueber Phagocytose und die Entstehung von Riesenzellen. Anat. Anz. Bd. XX. No. 7. S. 188 und No. 8/9. S. 193.

XVI. Explanation of Plates I, II.

The following abbreviations apply to all plates in which they occur.

a	artery.	*l*	lymphoid tissue.
b.c	blood cell.	*leu*	leucocyte.
b.s	blood sinus.	*ph*	phagocyte.
b.s.c	central blood sinus.	*p.m*	pigment mass.
b.s.p	peripheral blood sinus.	*r*	reticulum.
c	capsule.	*r.c*	reticulum cell.
e.c	endothelium cell.	*s.l*	strand of lymphoid tissue.
g.c	germ centre.	*trb*	trabecula.
i.m.f	involuntary muscle fibre.	*v*	vein.

Fig. 1. Portion of a section of spleen (as seen under a magnification of 50 diameters). *m.c.a* Malpighian corpuscles containing artery; *m.c.g* Malpighian corpuscles containing germ centre; *spl.p* Spleen pulp. (Reduced to $^1/_2$.)

Fig. 2. Section of typical hæmal gland (as seen under a magnification of 45 diameters). The sinus contains blood cells in abundance and a few scattered leucocytes. (Reduced to $^1/_2$.)

Fig. 3. Section of a portion of Dog's hæmal lymphatic gland (as seen under a magnification of 105 diameters). *s.s* small sinus. All sinuses contain a mixture of blood and lymph. (Reduced to $^1/_2$.)

Fig. 4. Portion of section of lymphatic gland of pig (as seen under a magnification of 50 diameters). The sinuses contain lymph corpuscles only. (Reduced to $^1/_2$.)

Fig. 5. Section passing through the sinus of a hæmal gland of the rat, stained hæmulum and eosin (as seen under magnification of 250 diameters). Showing a vein leading directly from the sinus and other vessels being conducted by lymphoid strands to the general mass of adenoid tissue. *ca* capillary; *e.c.c* endothelium cell of capillary, continuous with cell of adjoining sinus; *f* fat cell;[1]) *t.a.a* tunica adventitia of vein, continuous with capsule.

Fig. 6. A germ centre from a sheep's gland, stained Heidenhain's iron hæmatox. and eosin (as seen under a magnification of 1000 diameters). *c.m* cell undergoing karyokinetic division; *l.t* general mass of lymphoid tissue.

[1]) The fat surrounding these glands is in the rat not of the ordinary variety.

Fig. 7. General dissection of hæmal glands in a rat, showing the vascular and nervous supply. On the right of the figure, near the anterior end of the kidney, is the "renal group" of glands, 3 glands are present. On the left of the aorta the spleen and stomach are thrown over to expose the omentum slinging them, and 4 glands contained in it. *ao* aorta; *c* caecum; *k* kidney; *r.g* renal gland; *s.c* suprarenal; *s.g* splenic gland; *sp* spleen; *st* stomach; *ur* ureter; *v.c* vena cava. In front of the aorta and vena cava lies the aortic nerve plexus and its branches. The splenic and renal vessels and branches are in view. Small twigs run to the glands. (Reduced to $^2/_3$.)

Fig. 8. Vertical section of hæmal gland of rat, stained hæmalum and eosin (as seen under a magnification of 105 diameters). The gland is cut at right angles to the numerous strands of lymphoid tissue issuing from the general mass. The section illustrates the general arrangement of the lymphoid tissue and sinuses, which are filled with blood and phagocytes. Masses of brown pigment occur in the adenoid tissue. (Reduced to $^2/_3$.)

Fig. 9. Small portion of last (as seen under a magnification of 1000 diameters). *e.c.c* endothelium cell lining capillary;[1]) *l.h.c* large hyaline cell; ph^1 Phagocyte containing two spherical masses of hæmoglobin; ph^2 Same as ph^1 with erythrocyte also; ph^3 Phagocyte full of pigment.

Fig. 10. Section of head kidney of Cyclopterus lumpus stained saffranin and light green[2]) (as seen under a magnification of 330 diameters).

Fig. 11. Series of sketches of phagocytes, illustrating the process of blood destruction (as seen under a magnification of 2000 diameters). Stained hæmalum and eosin. *a*) Large hyaline cell; *b*) similar cell dividing; *c*) a cell containing an ingested blood cell which lies in a vacuole; *d*) phagocyte containing a number of unchanged red cells (this was taken from a section stained in bulk in Ehrlich and eosin; *e*) and *f*) phagocytes containing red cells and globules of pigment of various size; *g*) phagocyte containing spherical masses of deeply stained hæmoglobin; *h*) another containing a small mass of pigment and in the top left hand corner a yellow pigment mass tinged red; *i*) phagocyte containig two nuclei, a mass of pigment tinged with red. In addition a body with red zone in centre and yellow zone surrounding it; black specks appear between the two layers; *j*) phagocyte containing two red cells, a mass of hæmoglobin and a leucocyte, also pigment; *k*) cell containing large mass of yellow pigment, and the remains of a leucocyte. Beneath the nucleus is one of the bodies seen in *i*); *l*) cell containing pigment; nucleus not apparent. (Reduced to $^1/_2$.)

Fig. 12. Section of gland of rat, arteries injected (as seen under a magnification of 105 diameters). The right half of the figure shows the sinus full of injection, the left half is dotted blue to represent lymphoid tissue. *c* capillary; a^1 artery in strand of lymphoid tissue; a^2 artery entering hilum; *f* fat with blood vessels injected. (Reduced to $^1/_2$.)

[1]) These cells should resemble those lining the sinus, much more closely.

[2]) The saffranin does not show well in this sketch, as the colour was washed over pencil.

Fig. 13. Section of gland of rat. Veins injected (as seen under a magnification of 105 diameters). Lymphoid tissue dotted vlue, sinuses white, a certain amount of injection has passed into the sinus in three places. (Reduced to $^1/_2$.)

Fig. 14. Silver nitrate preparation of inner wall of capsule (as seen under a magnification of 600 diameters). Showing strands of white fibrous tissue and endothelium, near the hilum of the gland. (Reduced to $^1/_2$.)

Fig. 15. Sketch of trabecula from a hæmal gland of the ox (as seen under a magnification of 600 diameters). Showing endothelium cells e^1, and reticulum cells *r.c* containing pigment; e^2 is a cell containing an erythrocyte.

Fig. 16. Section of spleen (as seen under a magnification of 600 diameters) to show arrangement of reticulum and endothelium in the neighbourhood of a Malpighian body, seen on the right half of the figure. *leu.m* leucocyte in Malpighian body; *leu.s* leucocyte in sinus.

Fig. 17. Diagram of a lymphatic gland to show arrangement of adenoid tissue and sinuses, the latter filled with leucocytes, coloured blue, quite diagramatically: running towards the gland are diagramatic vessels. *A.L* Afferent lymphatic; *E.L* Efferent lymphatic; *A.B* Afferent blood vessel; *E.B* Efferent blood vessel. There is a large lymph supply, but the blood supply is small.

Fig. 18. Diagram of a hæmal lymphatic gland, the lettering is the same as in 17, showing general arrangement of tissues and the breaking up of the lymphoid tissue, also the large blood and lymph supply: the red dotting represents blood.

Fig. 19. Diagram of a hæmal gland, showing preponderance of sinus; the lymphoid tissue diminished and broken up. The sinus is filled with blood, only one or two leucocytes are represented: the lymph supply as indicated by the diagramatic vessels is very small, while the blood supply is large: the reticulum is denser than in 18. Lettering as before.

Fig. 20. Diagram of spleen, showing remains of lymphoid tissue in form of Malpighian corpuscles; the sinus, or "spleen pulp" is full of blood; the lymphatic vessels entering the gland are small, the bloodvessels large: the reticulum and trabeculae are very strong: lettering as before.

Buchdruckerei Richard Hahn (H. Otto), Leipzig.

2.
s.l.
m.c.a.
r.
trb.
l.
g.c.
b.s.p.
m.c.g.
c.
r.
trb.
1.
m.c.g.
m.c.a.
c.
trb.
spl.p.
trb.
3.
trb.
b.s.c.
ph.
b.s.p.
c.
ph.l.
6.
b.c.
s.
e.c.
l.l.
c.m.
c.m.
8.
l.
s.
c.m.
c.
pm.
c.
p.m.
ph.
s.
l.
bc.
leu.
a.
b.
f.
e.
d.
i.
c.
II.

he Haemolymph Glands and Spleen

10.

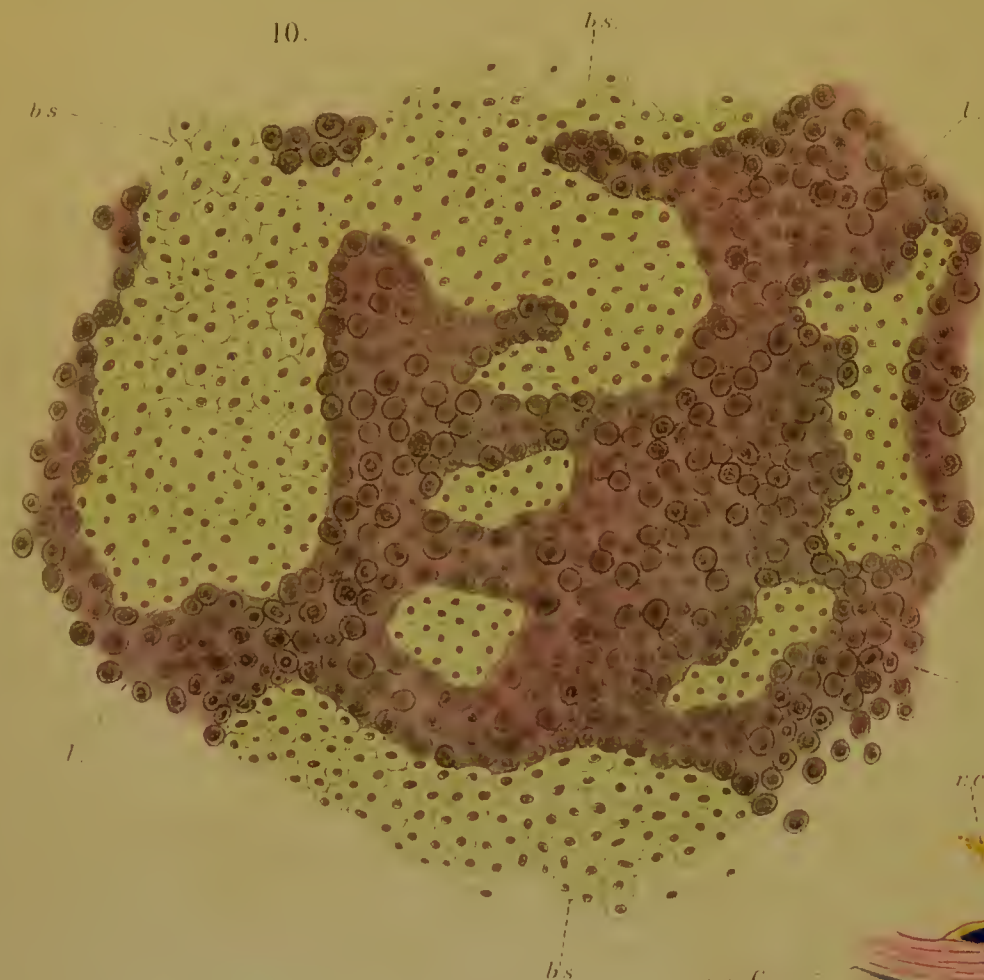

16.



12.

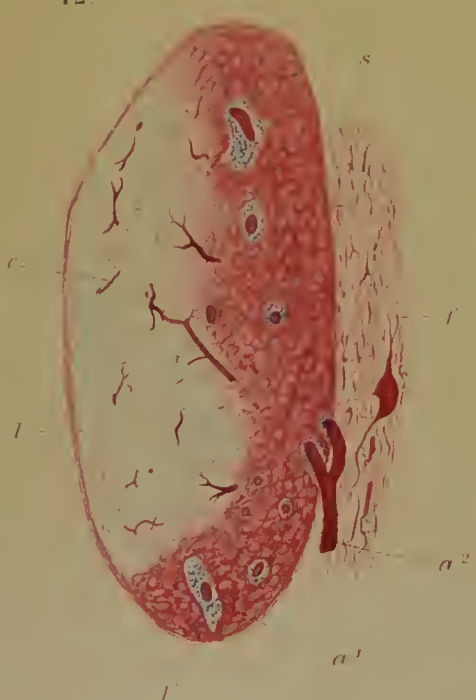

13.

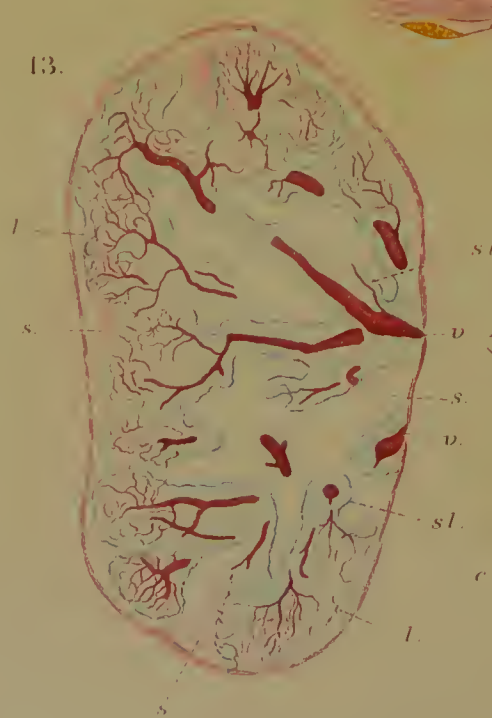

17.

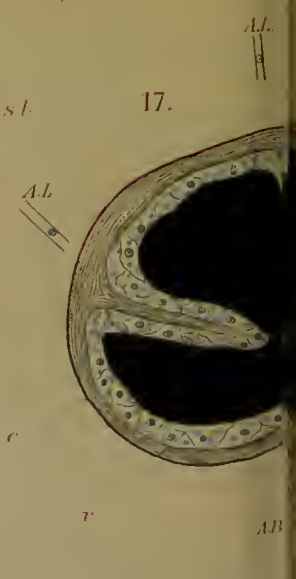

Thomas Lewis: The Structure and Func

the Haemolymph Glands and Spleen

Verlag von **Georg Thieme** in **Leipzig.**

Lehrbuch der allgemeinen Physiologie.

Eine Einführung in das Studium der Naturwissenschaften und der Medizin.

Von

Dr. J. Rosenthal,

o. ö. Professor der Physiologie an der Universität Erlangen.

Mit 137 Textabbildungen.

M. 14.50, geb. M. 16.50.

Die Descendenztheorie.

Vorlesungen über den Auf- und Niedergang einer naturwissenschaftlichen Hypothese

für

Studierende aller Fakultäten.

Von

Dr. Albert Fleischmann,

o. ö. Professor der Zoologie und der vergleichenden Anatomie zu Erlangen.

M. 6.—, geb. M. 7.—.

Formative Reize in der tierischen Ontogenese.

Ein Beitrag zum Verständnis der tierischen Embryonalentwickelung.

Von

Dr. Curt Herbst,

Privatdozent in Heidelberg.

M. 5.—.

Grundriss der Entwickelungsmechanik.

Von

Dr. Wilhelm Haacke.

M. 12.—, geb. M. 13.50.

Mechanismus und Vitalismus.

Von

Dr. Gustav Wolff,

Privatdozent in Basel.

M. 1.—.

Beiträge zur Kritik der Darwinschen Theorie.

Gesammelte und vermehrte Abhandlungen.

Von

Dr. Gustav Wolff,

Privatdozent in Basel.

M. 2.—.

Verlag von **Georg Thieme** in **Leipzig.**

Biologisches Centralblatt

unter Mitwirkung von

Dr. K. Goebel und **Dr. R. Hertwig**
Professoreu in Müuchen,

herausgegeben von

Dr. J. Rosenthal
Prof. der Physiologie in Erlangen.

Das »Biologische Centralblatt« hat den Zweck, die Fortschritte der biologischen Wissenschaften zusammenzufassen, und den Vertretern der Einzelgebiete die Kenntnisnahme der Leistungen auf den Nachbargebieten zu ermöglichen. Zur Erreichuug dieses Zieles enthält das Blatt:

1) Original-Mitteilungen, besonders Berichte über Forsehungsresultate, welche ein allgemeineres Interesse über den Kreis der engeren Fachgenossenschaft hinaus beanspruchen können.

2) Referate, welche den Inhalt anderweitig veröffentlichter Arbeiten in knapper, aber verständlicher Weise wiedergeben. Besonders auch Selbstanzeigen, in denen die Herren Gelehrten von ihren an anderen Stellen ersehienenen Arbeiten, soweit sie in das Gebiet unseres Blattes gehören, sachlich gehaltene Auszüge liefern.

3) Zusammenfassende Uebersichten. Während die Referate einzelne Arbeiten behandeln, wird über wichtigere Fortschritte der Wisseuschaft in besonderen, zusammenfassenden Uebersichten Bericht erstattet, um so die dauernden Bereicherungen unseres Wissens festzustellen und den Boden kennen zu lehren, auf welchen neue Bestrebungen mit Aussicht auf Erfolg sieh stützen können.

4) Besprechungen von Büchern, bibliographische Nachweise und kürzere Notizen.

Ausser den Hauptfächern der biologisehen Naturwissenschaften (Botanik, Zoologie, Anatomie und Physiologie) mit ihren Nebenfächern (Entwickelungsgeschichte, Paläontologie u. s. w.) finden auch Ergebnisse andrer Wissenschafteu Berücksichtigung, soweit sie ein biologisches Interesse haben, somit alles, was im stande ist, die wissenschaftliche Erkenntnis der Lebenserseheinungen zu förderu und zu vertiefen.

Das Centralblatt erscheint in Nummern von je 2—4 Bogen, von denen 24 einen Band bilden. In jedem Monat werden 2 Nummern ausgegebeu. Jährlich also ein Band von ca. 900 Druckseiten.

Preis des Bandes 20 Mark.

(Band I—XXI **Mk. 240.—** anstatt Mk. 348.—.)

Bestellungen nimmt sowohl die Verlagshandlung wie jede Buchhandlung oder Postanstalt entgegen.

Probehefte auf Verlangen gratis und franco.